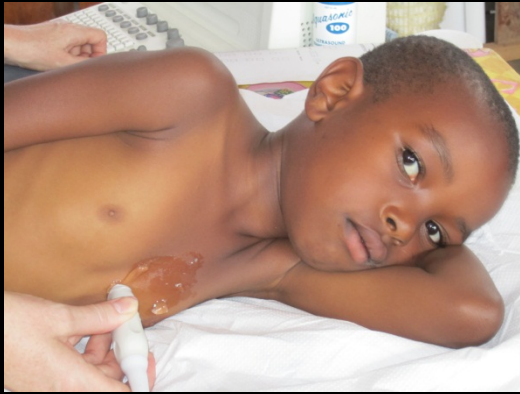

Echo Cases

ASE, PSE, USN

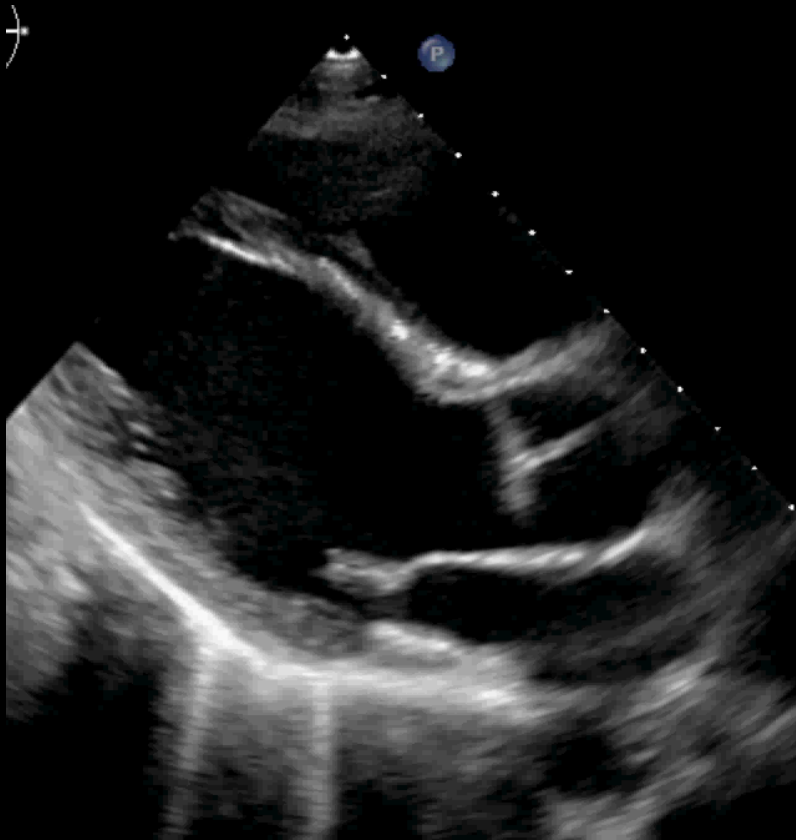
David Adams, RCS, RDCS



Cases

- PE, Tamponade
- Dilated chambers
- MR, TR, AI
- Hypertrophies
- Assorted stuff

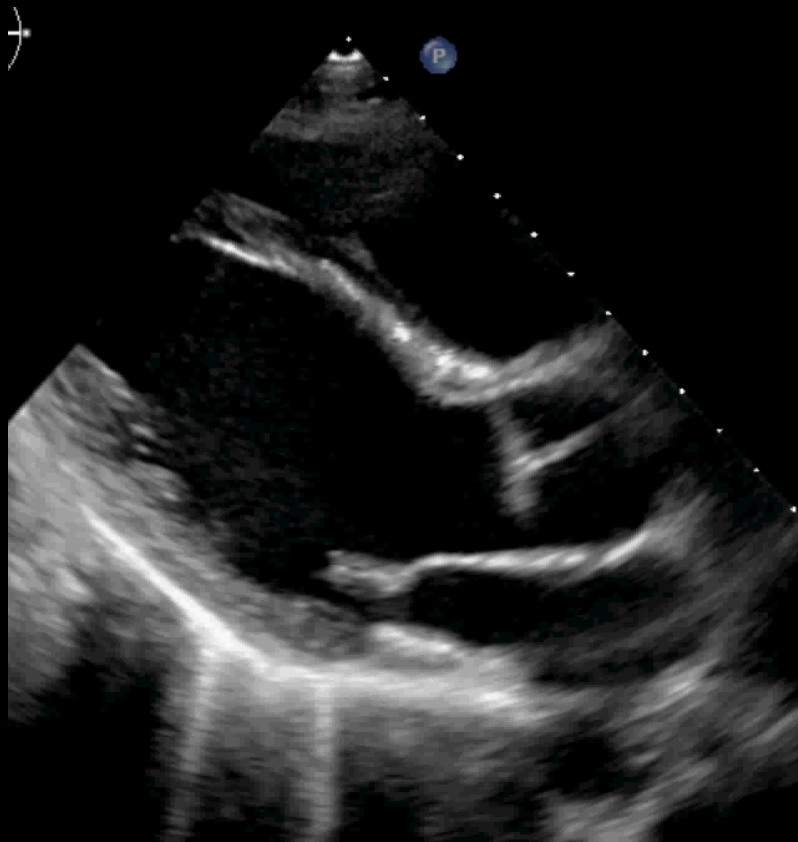
Normal



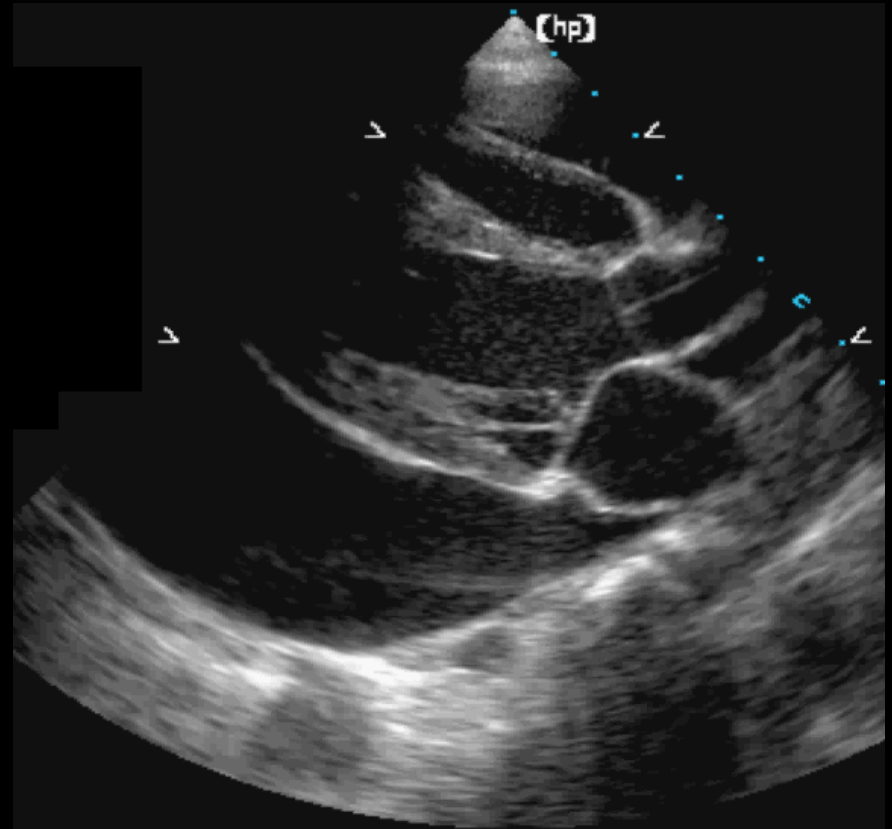
How I Assess

- Follow the flow
- LA Size vs Ao
- MV
- LV Size & Fx
- AoV & root
- RV size
- ? PE

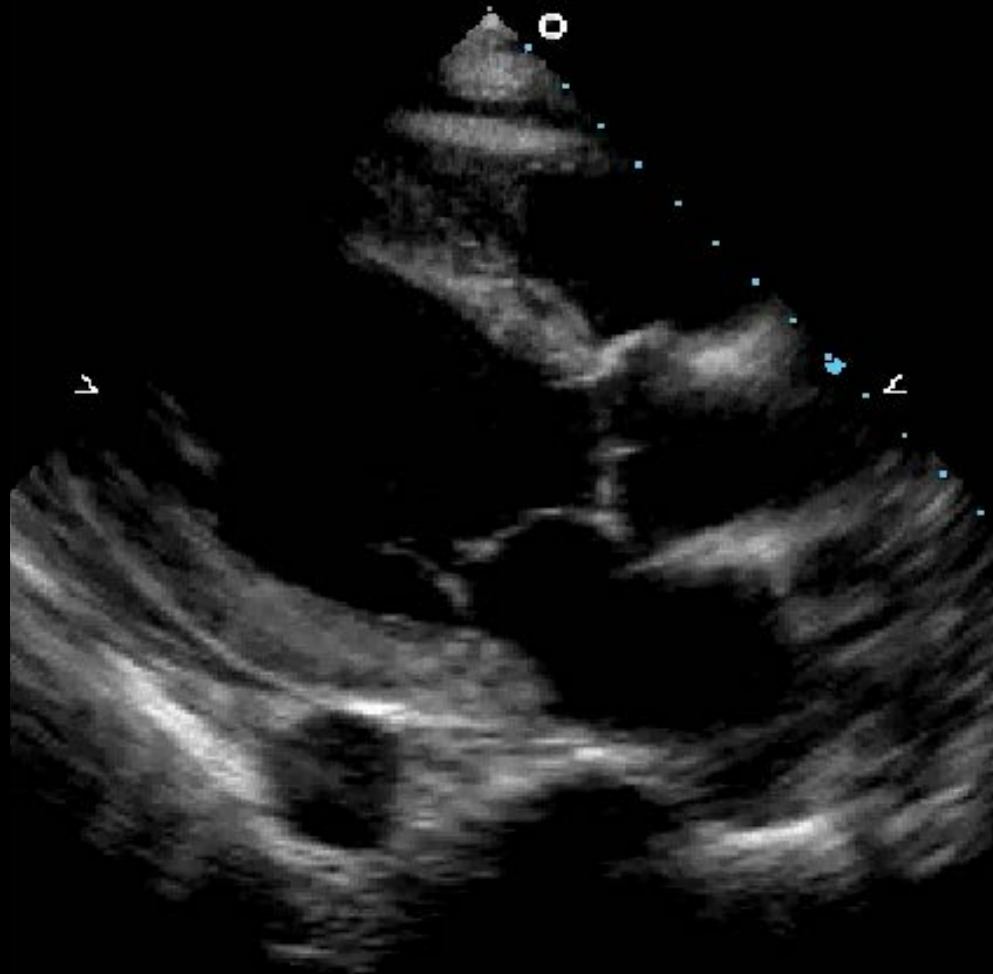
Normal



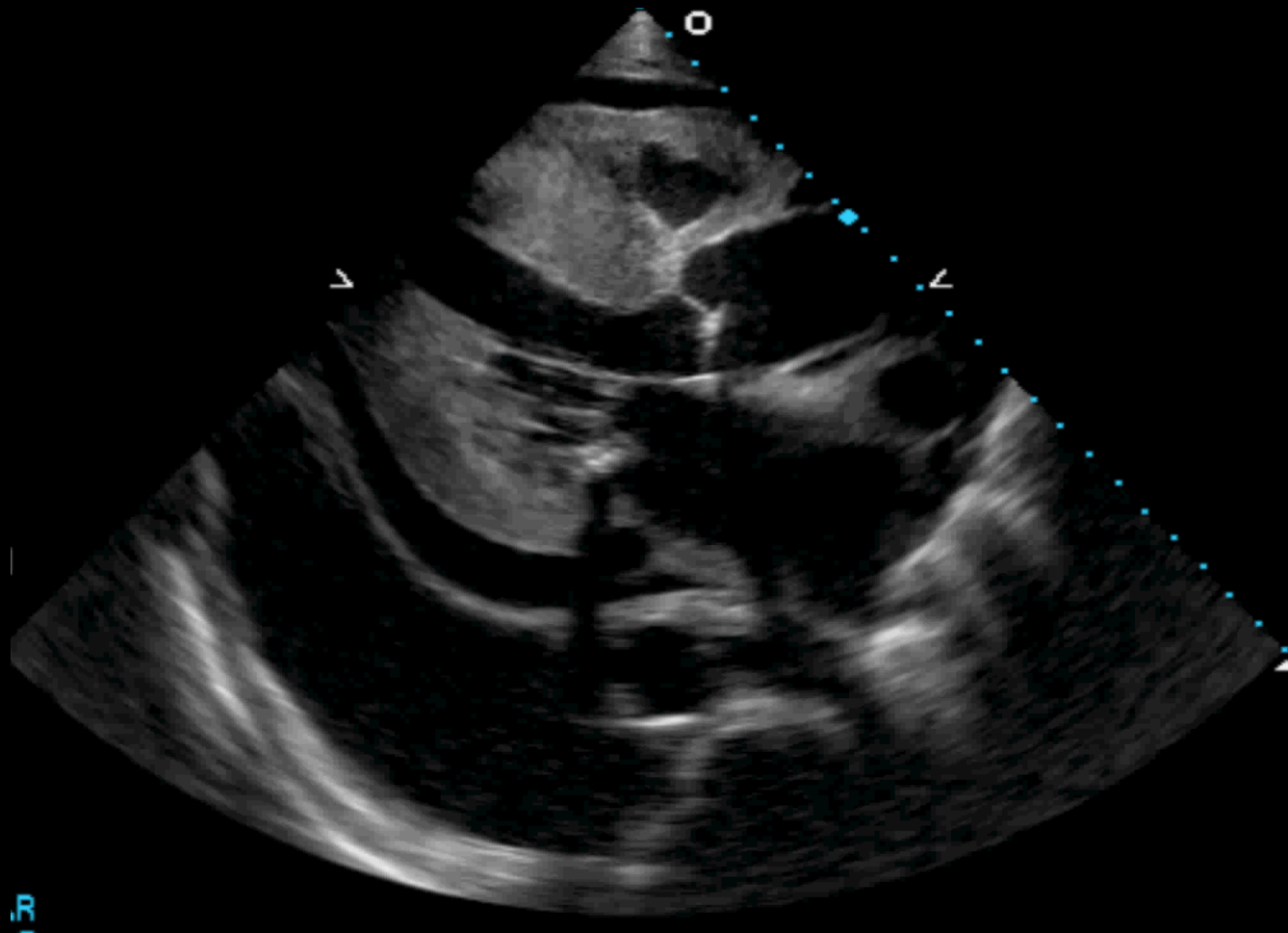
Large PE



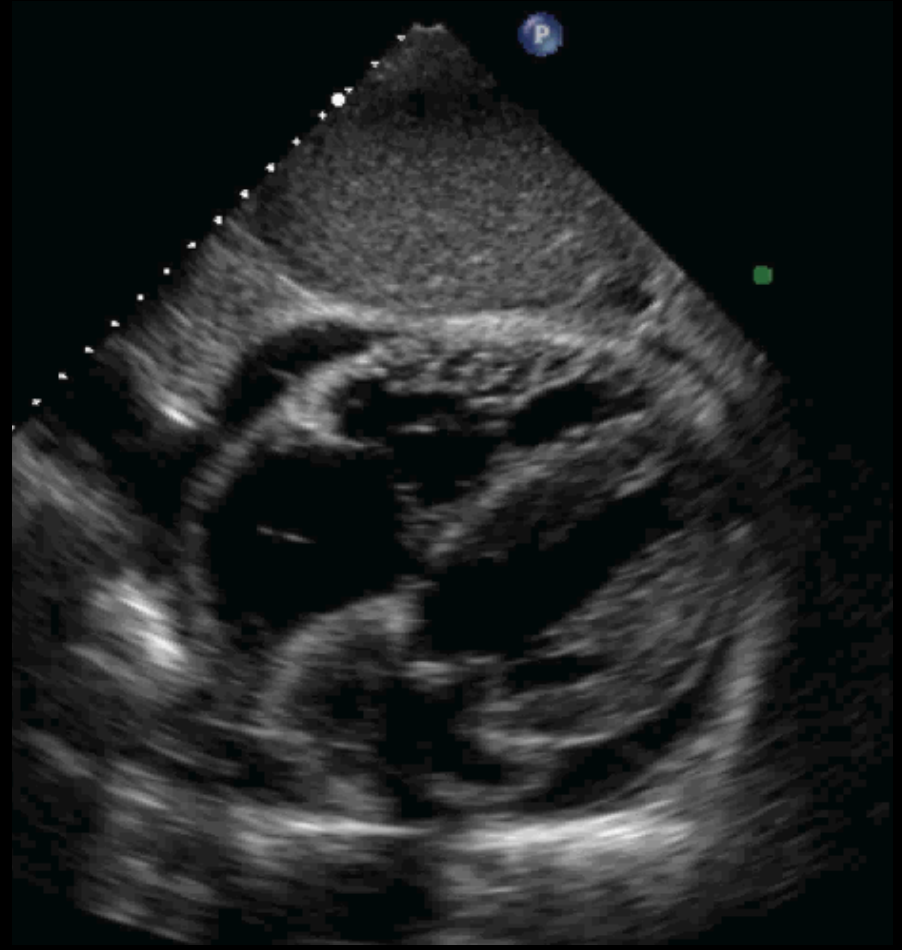
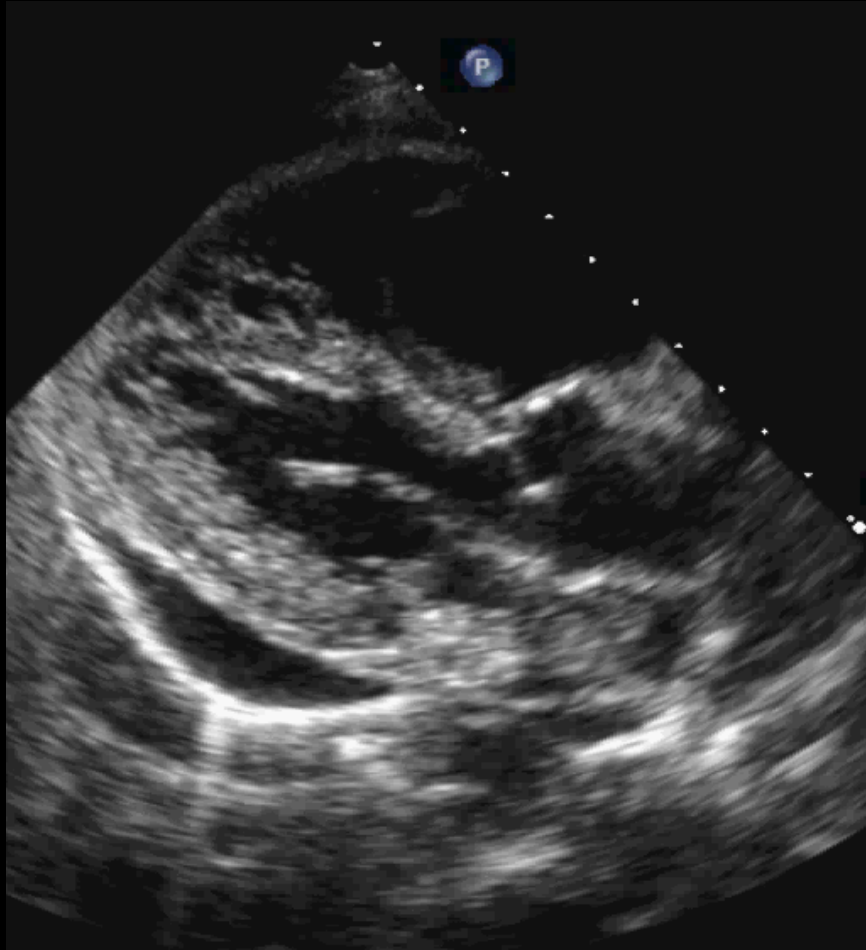
Small PE



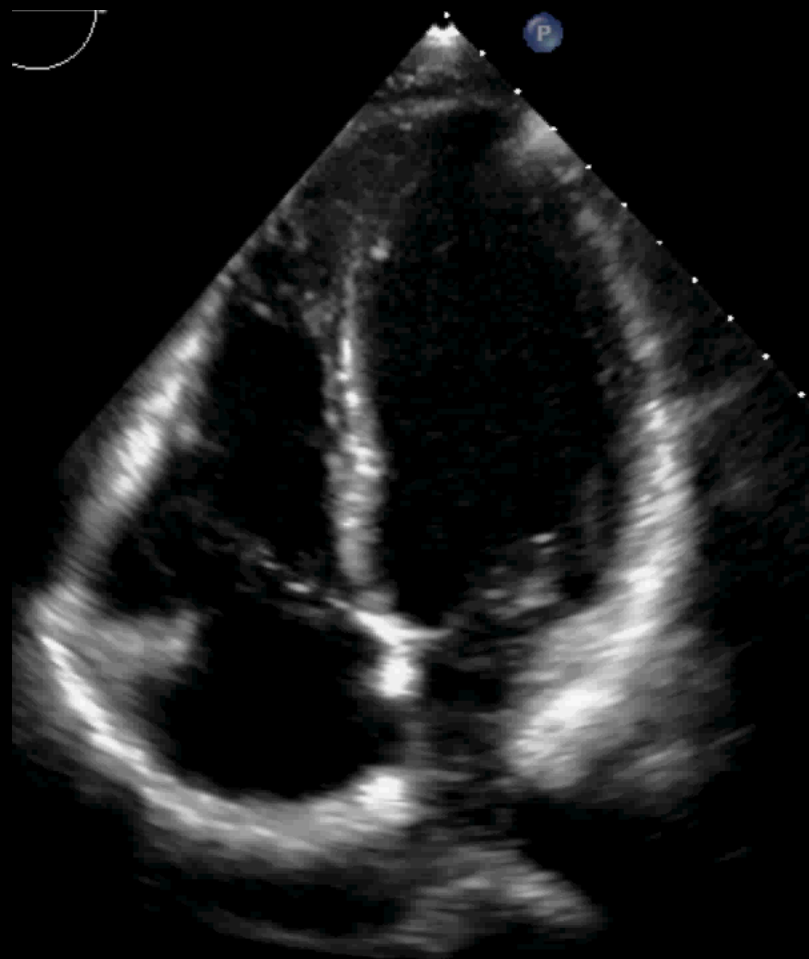
PE vs Pleural



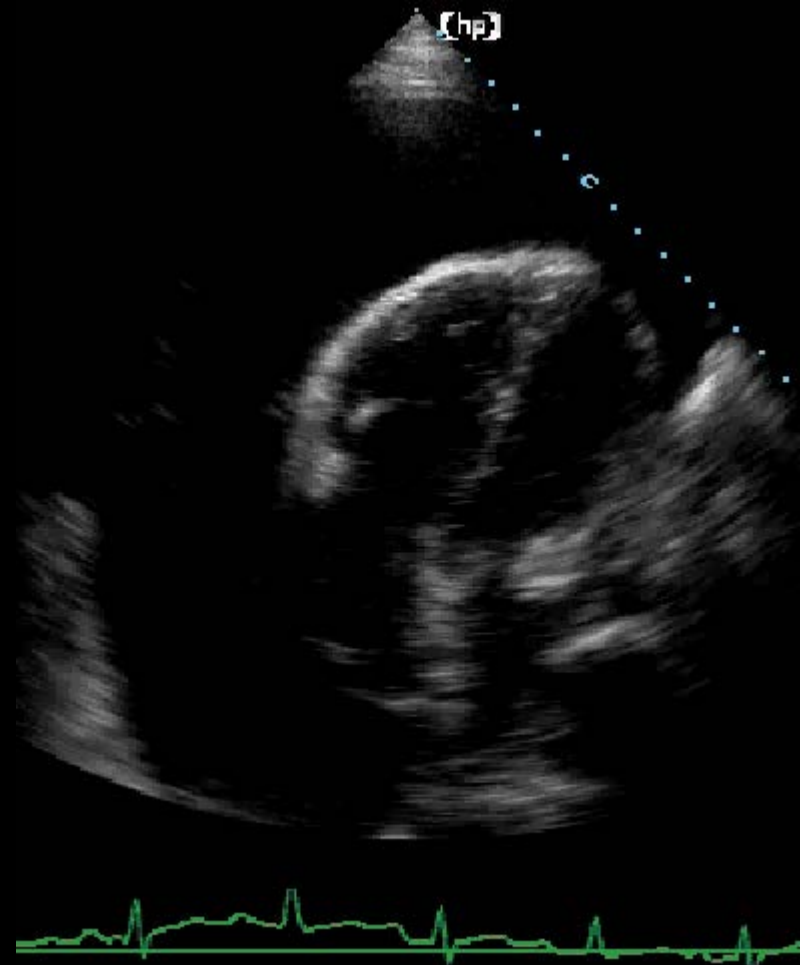Moderate PE's



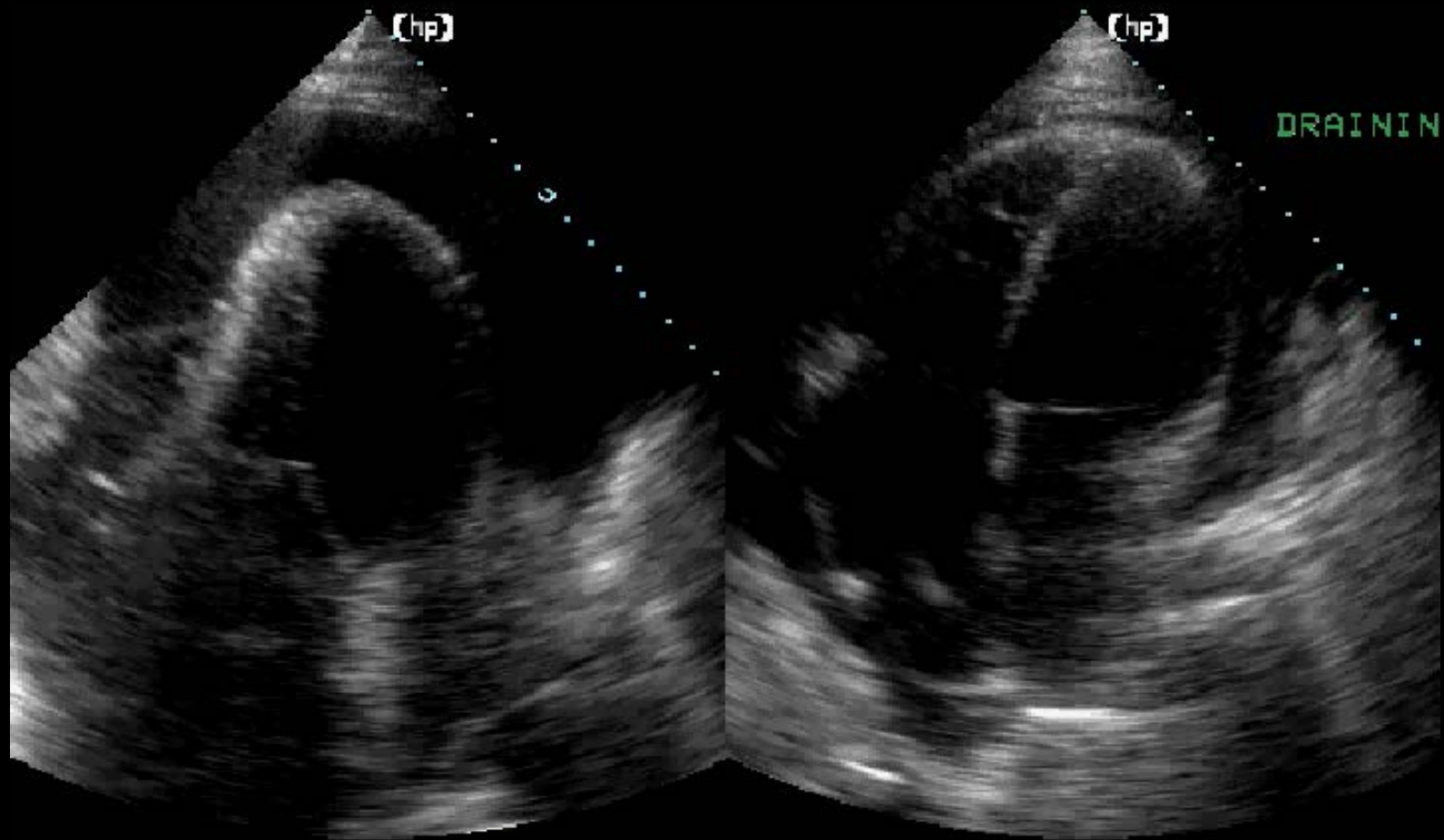
Normal



Large PE

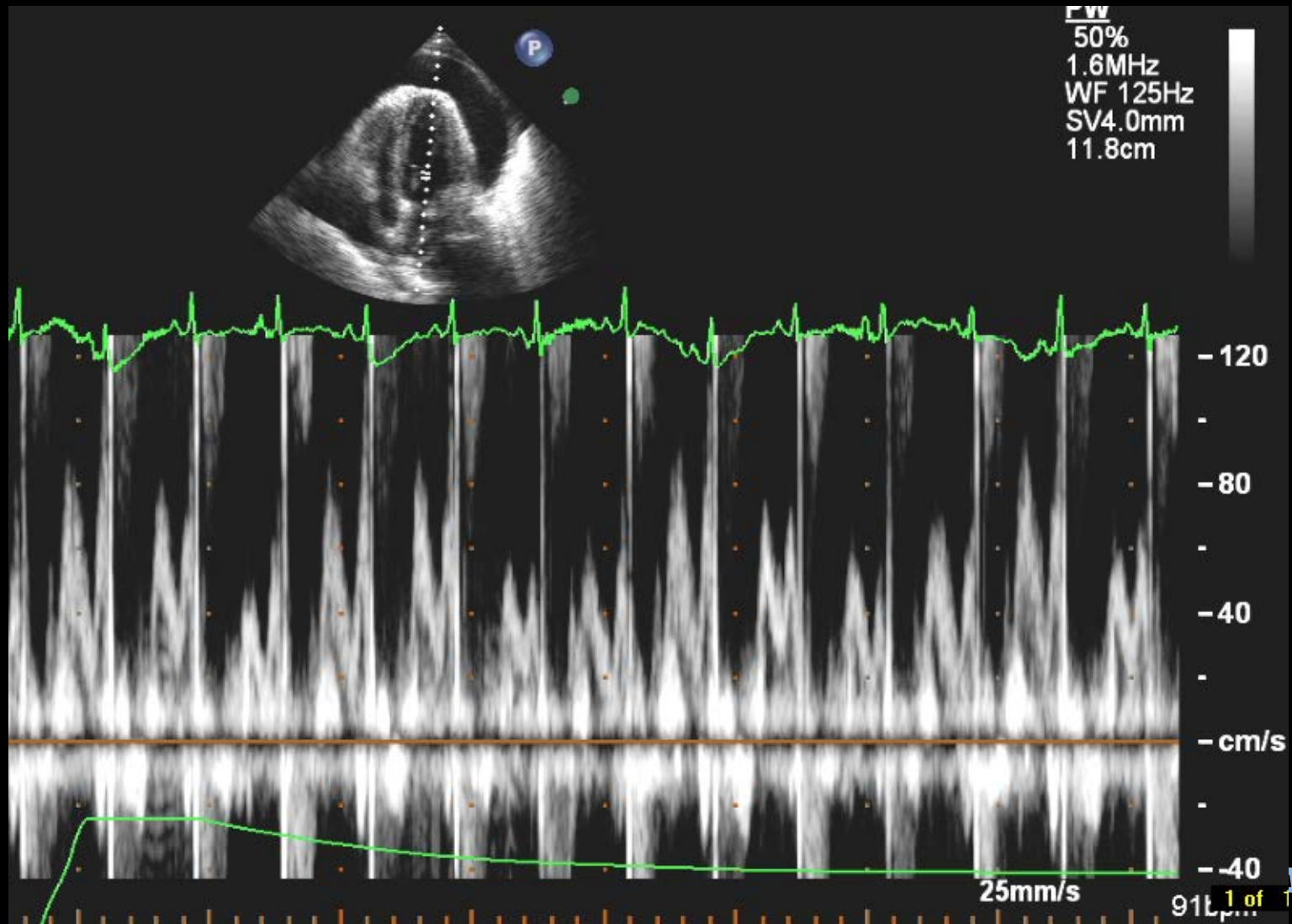


Pericardial Tap

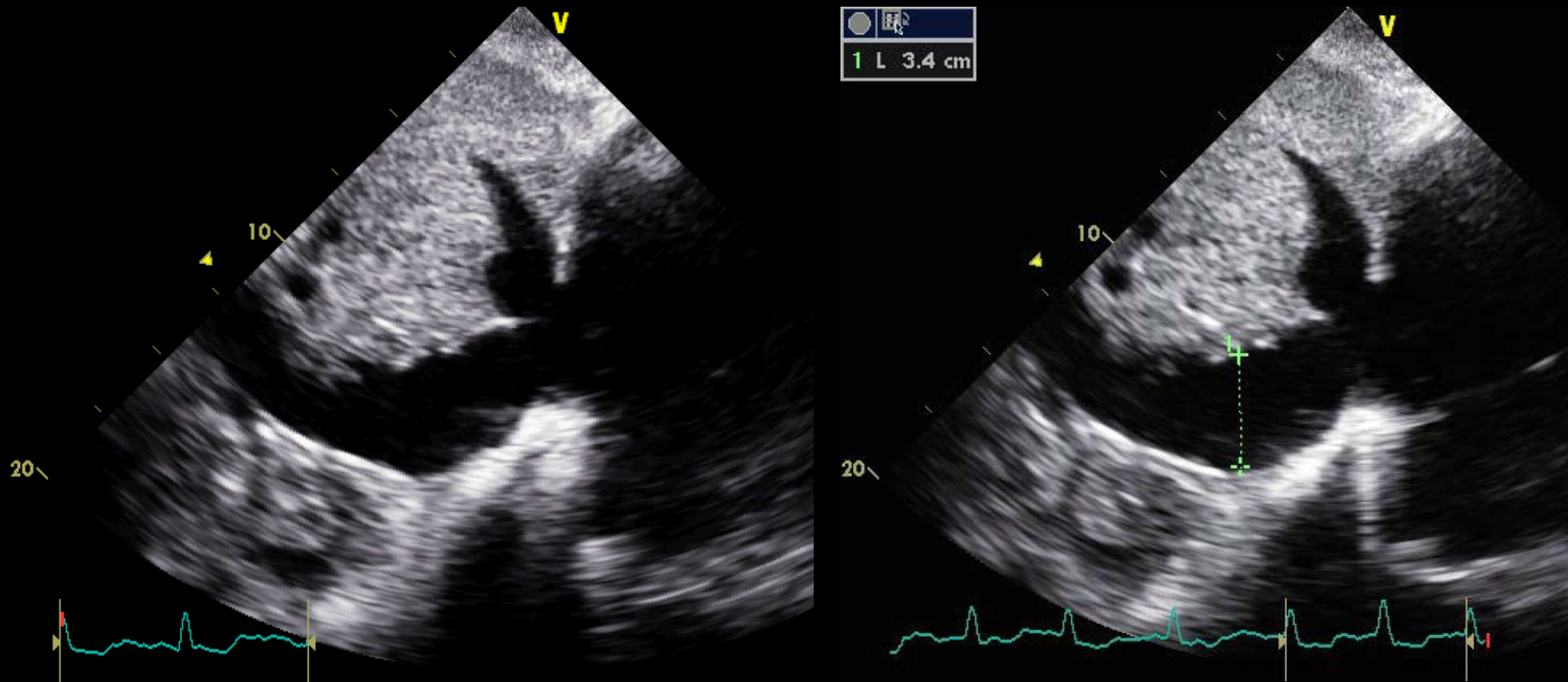


Tamponade??

Resp Flow Variation



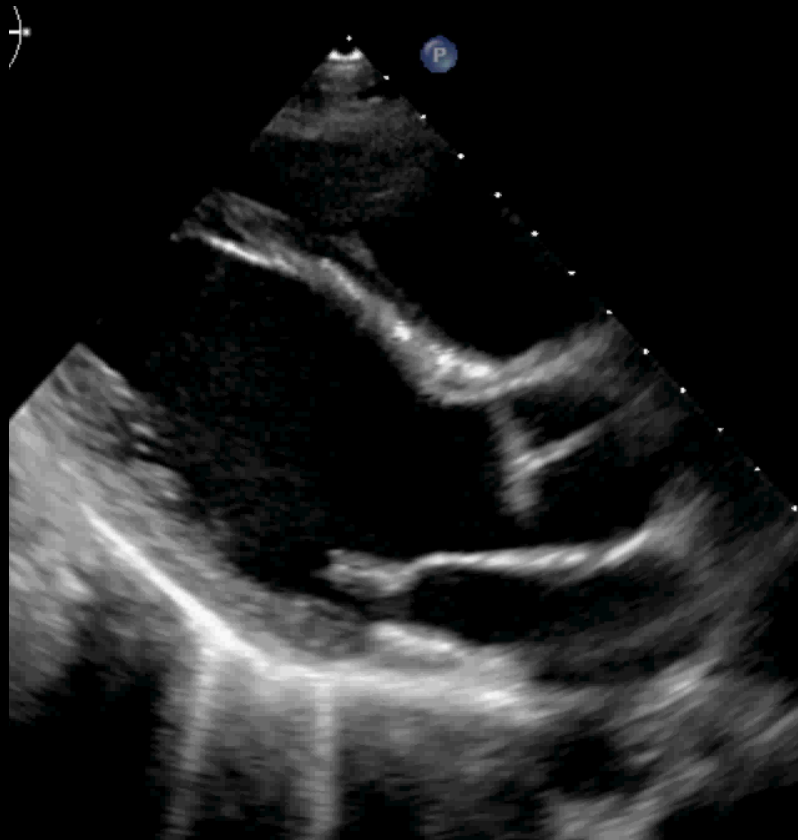
Dilated IVC



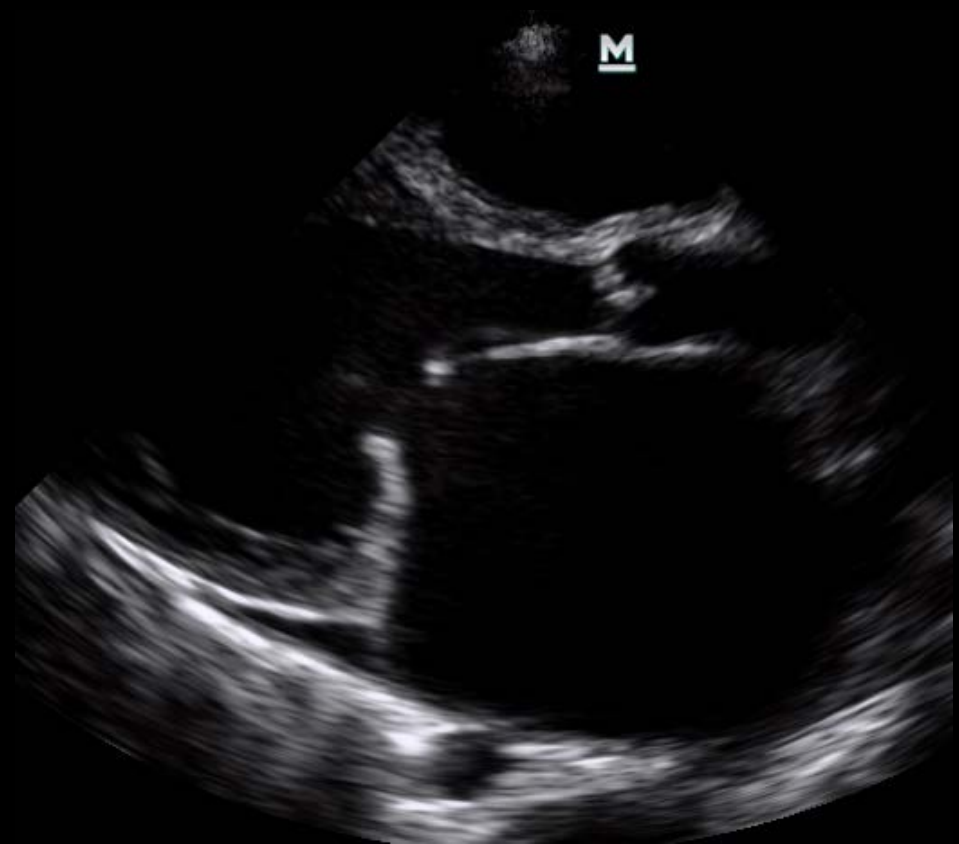Cases

- PE, Tamponade
- Dilated chambers

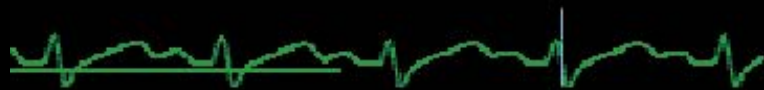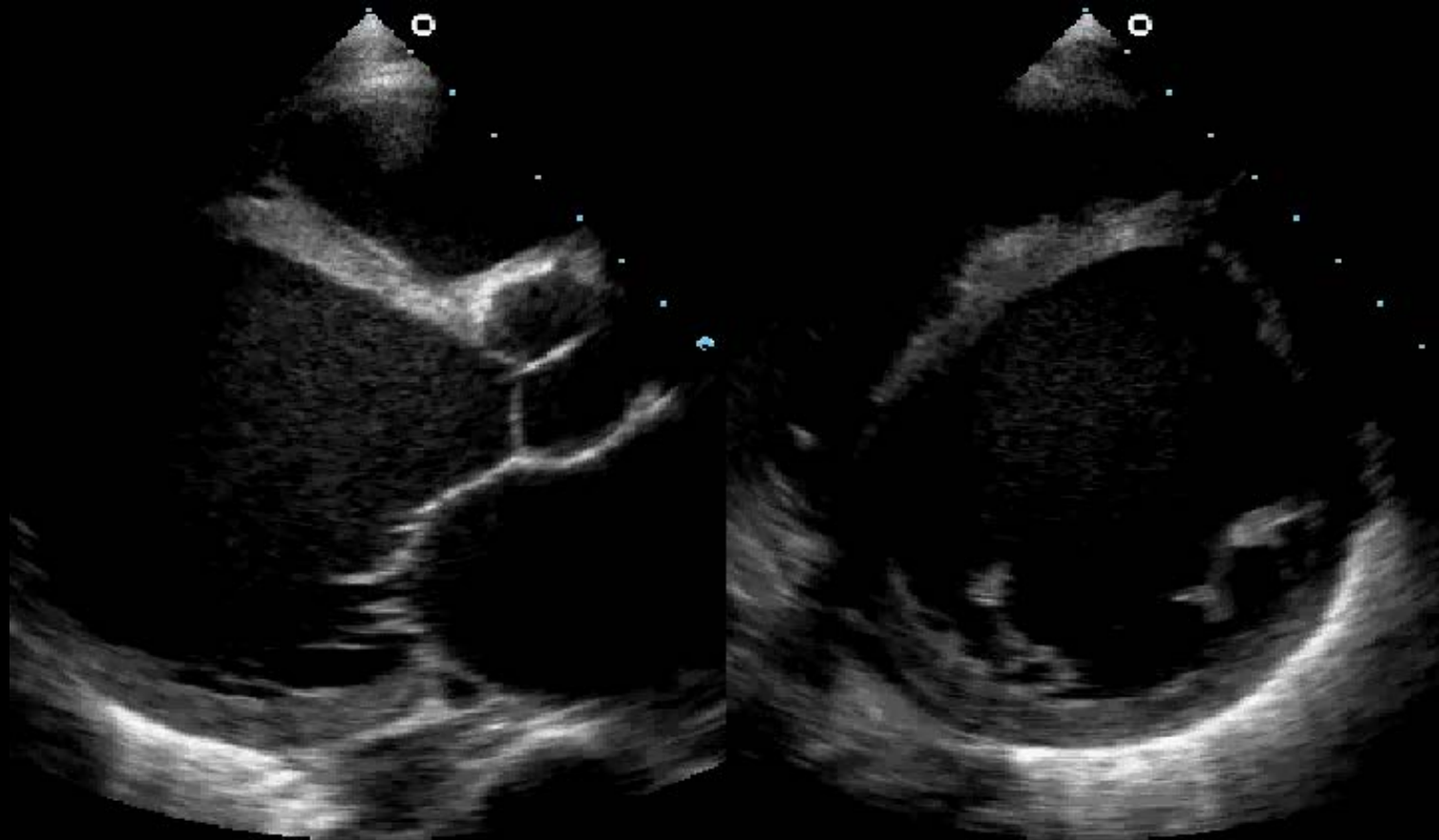
Normal



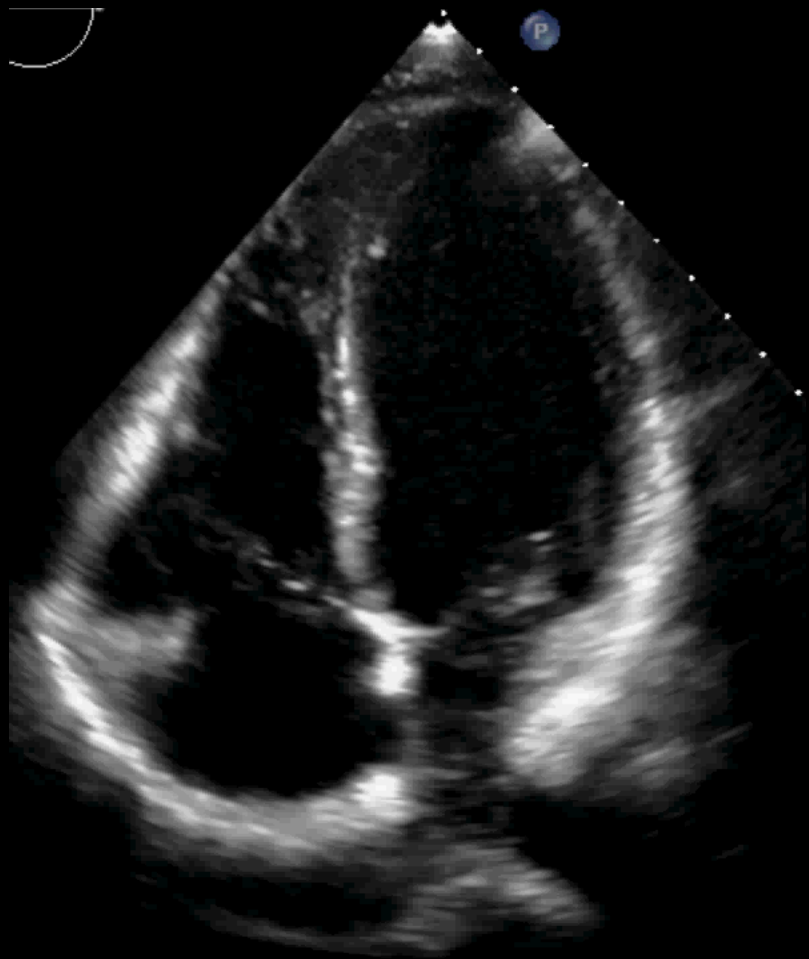Dilated LA



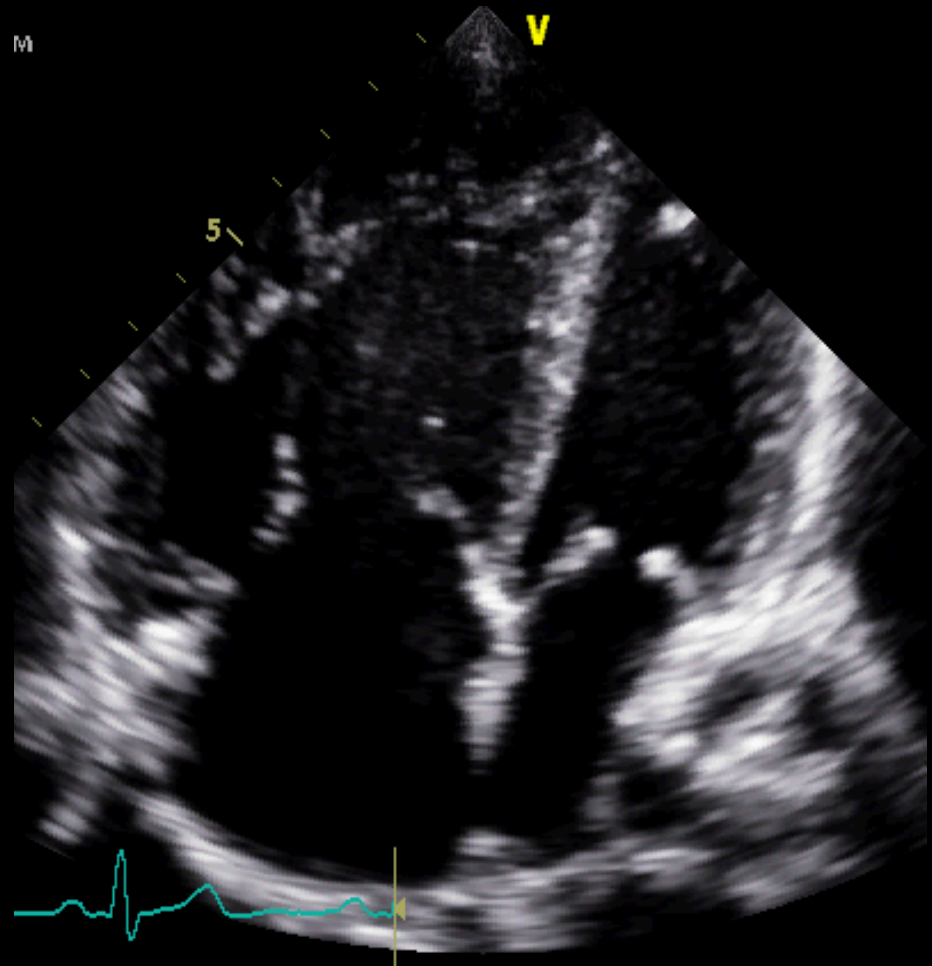
Dilated CM



Normal



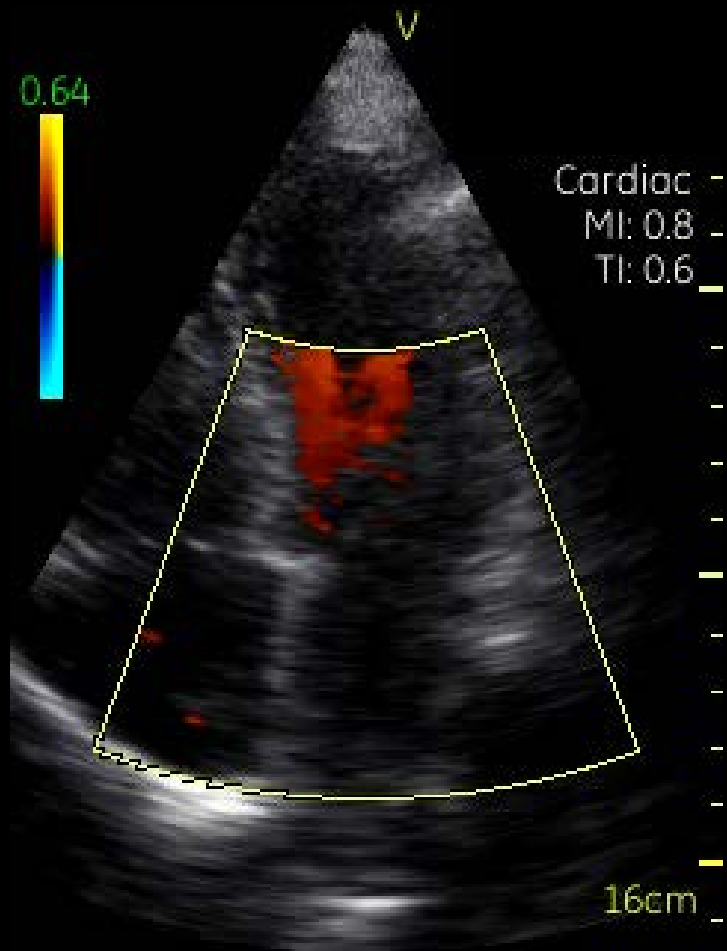
Dilated RV/RA



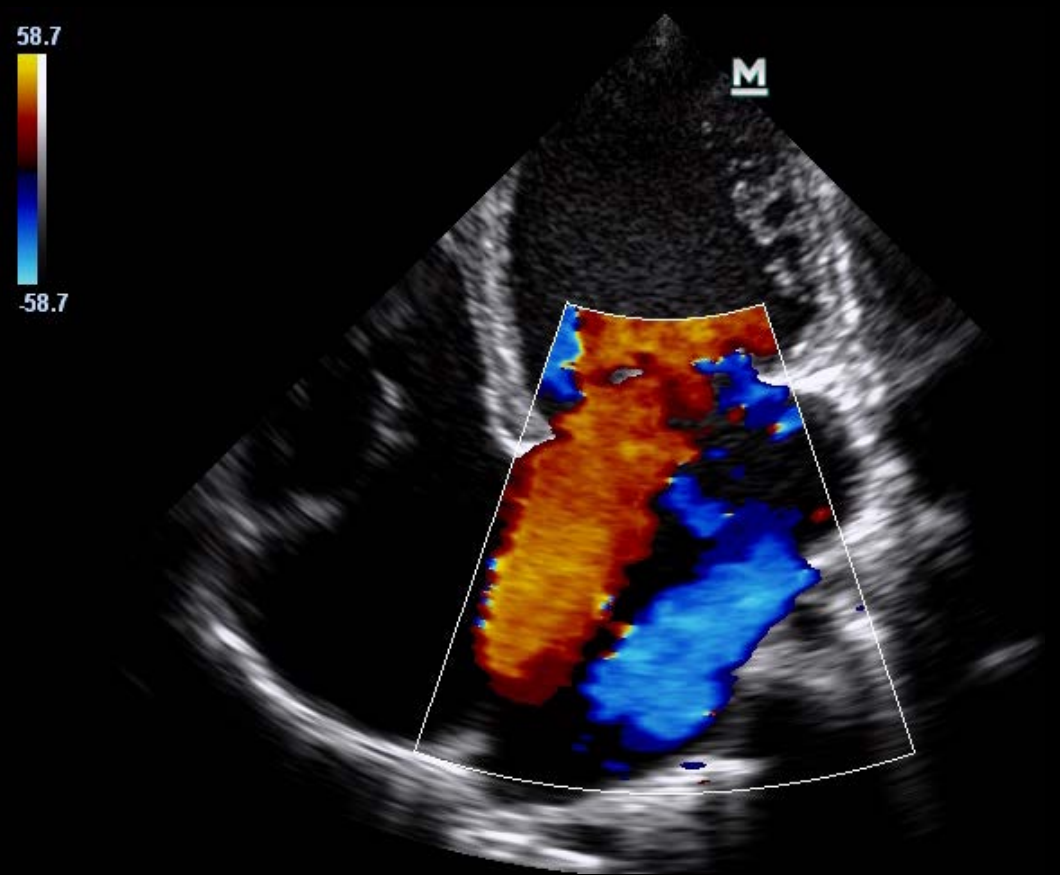
Cases

- PE, Tamponade
- Dilated chambers
- MR, TR, AI

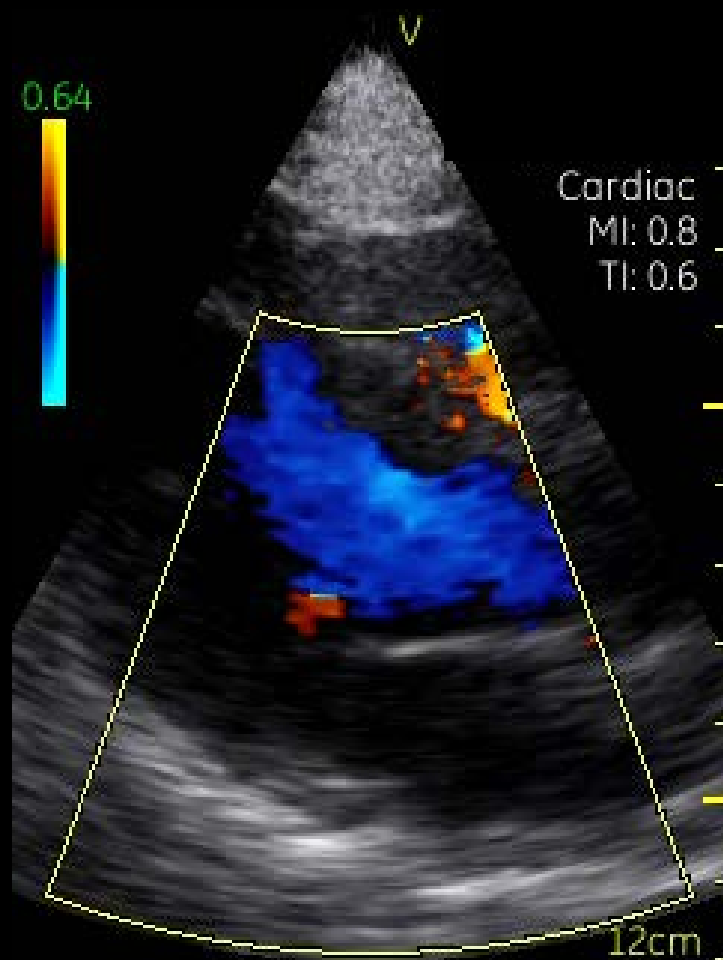
Normal



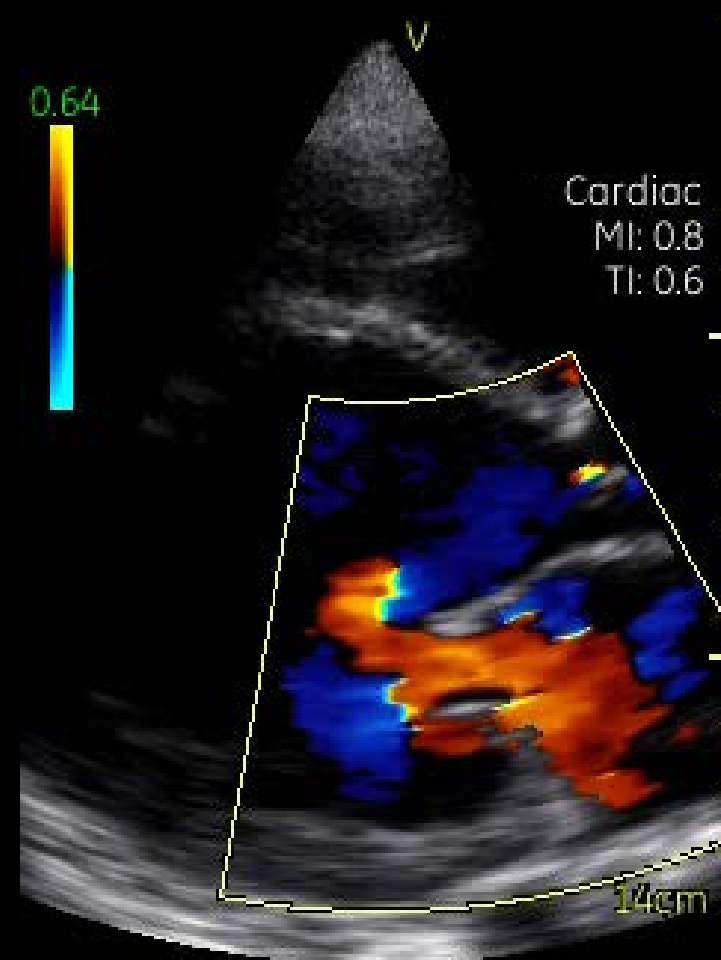
Severe MR



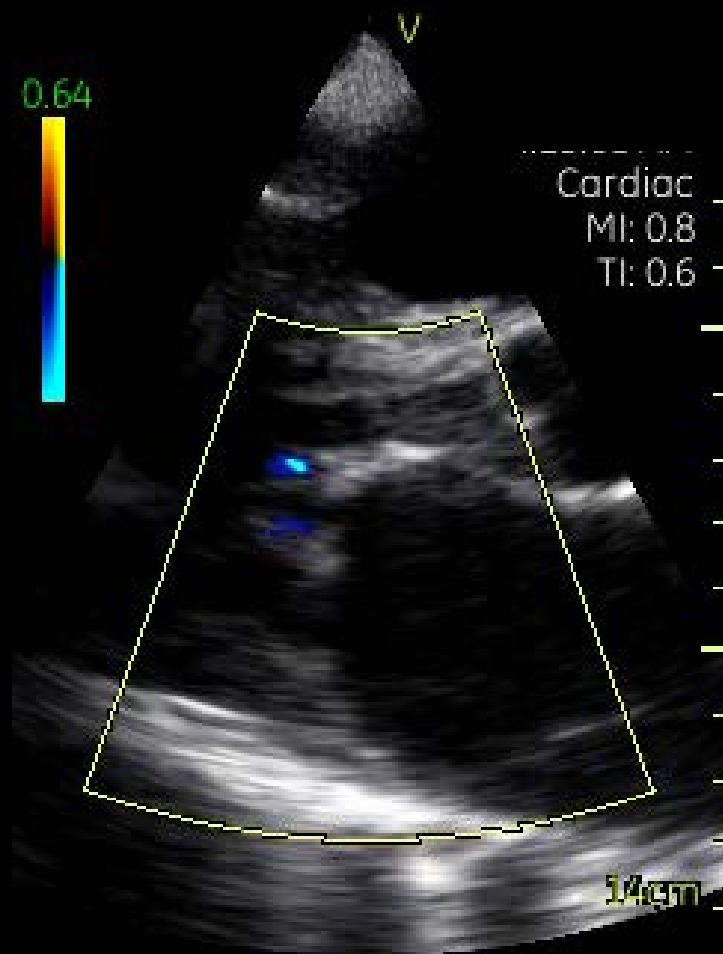
Normal



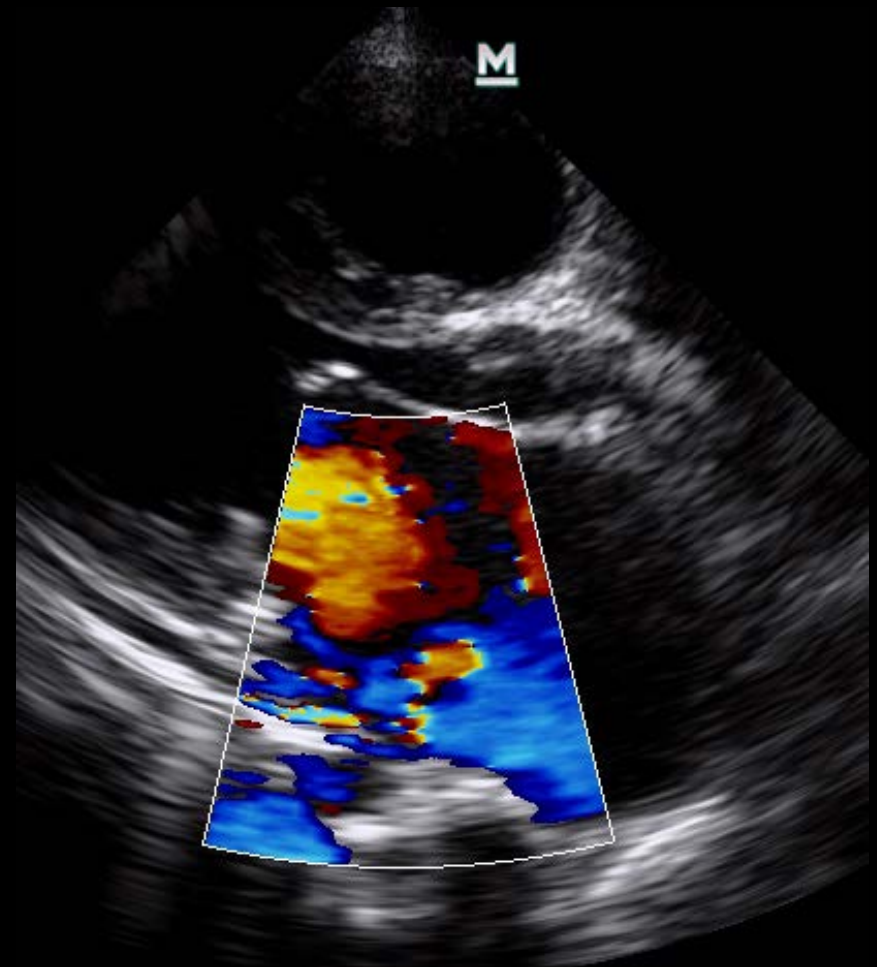Dilated CM - MR



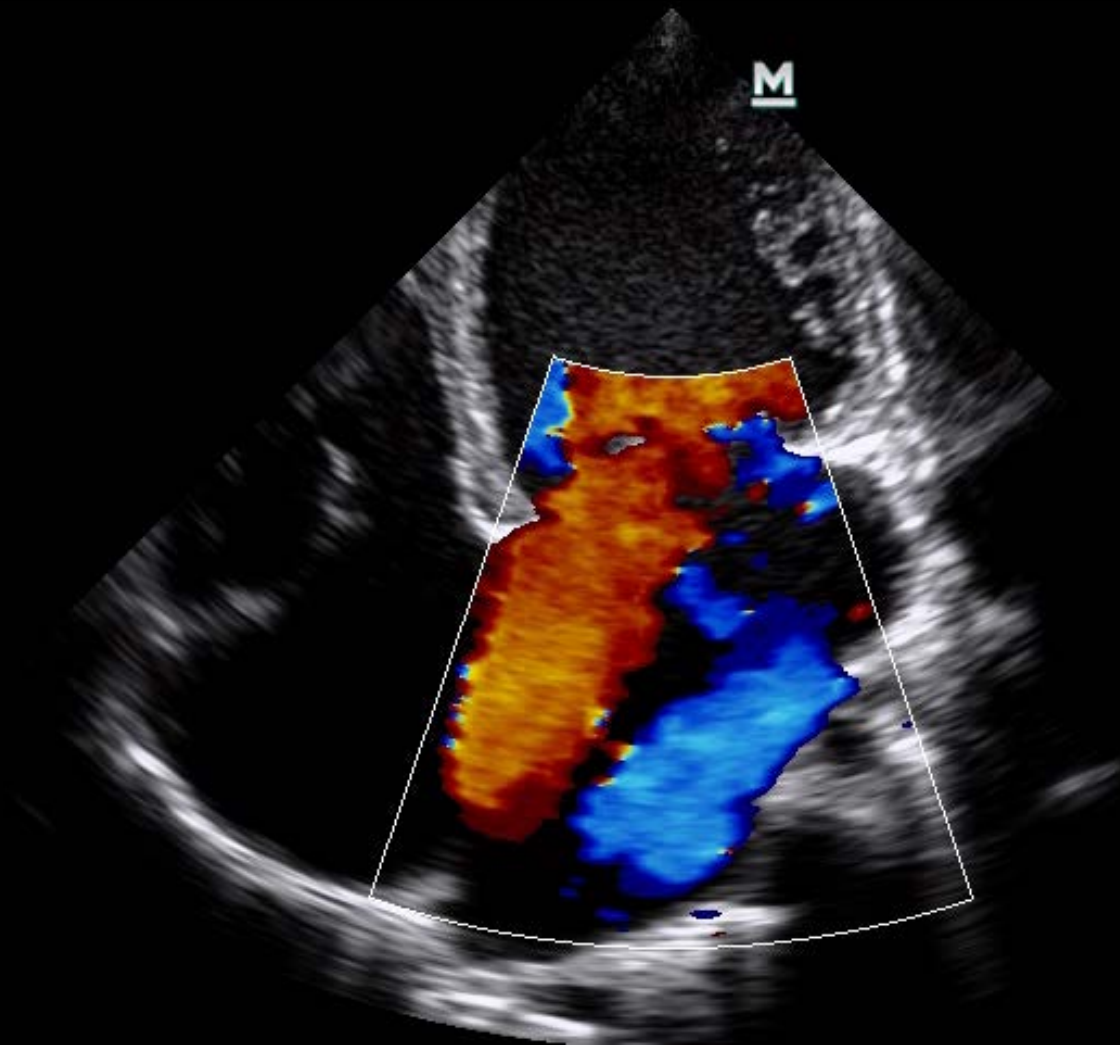Mild MR



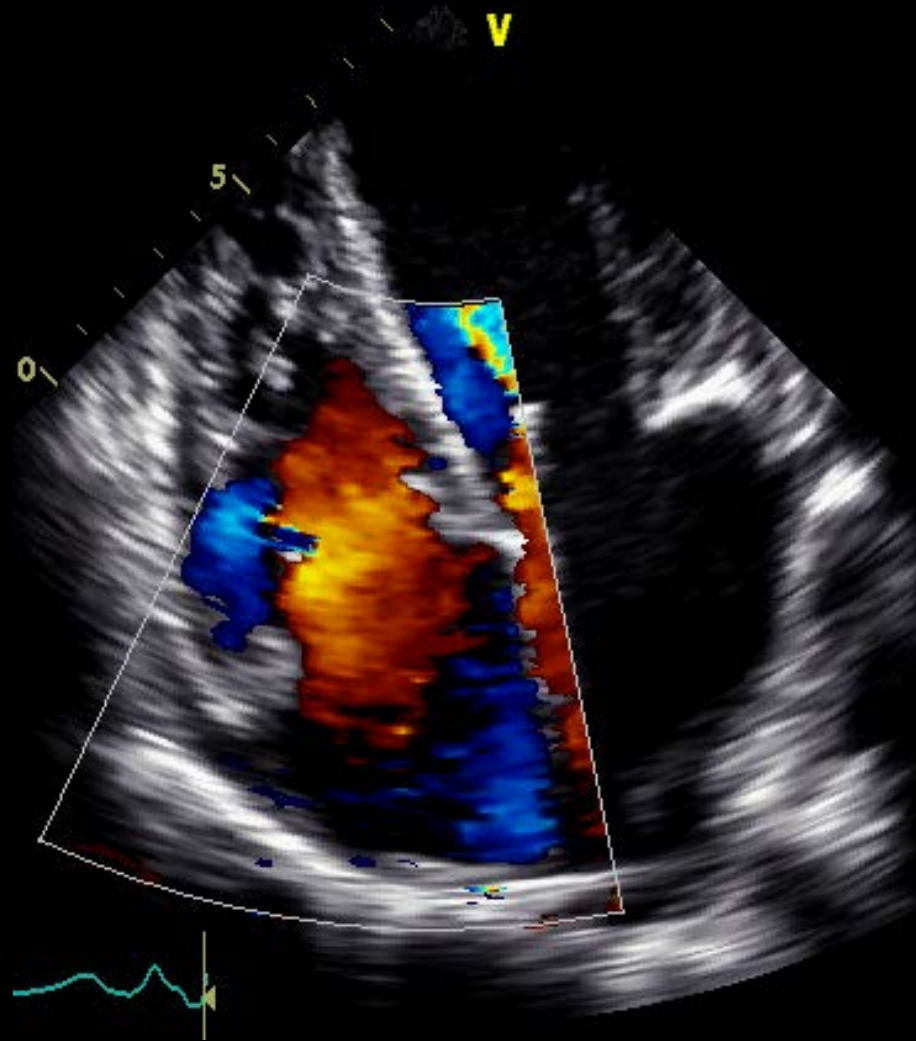Sev. MR



Apical 4 CH with MR

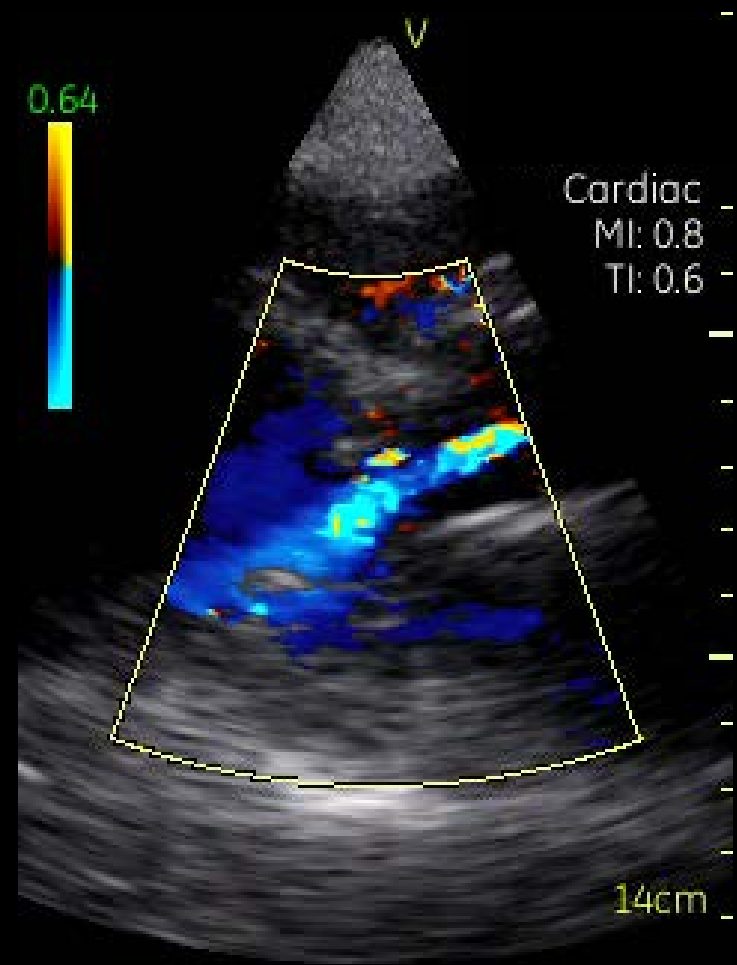
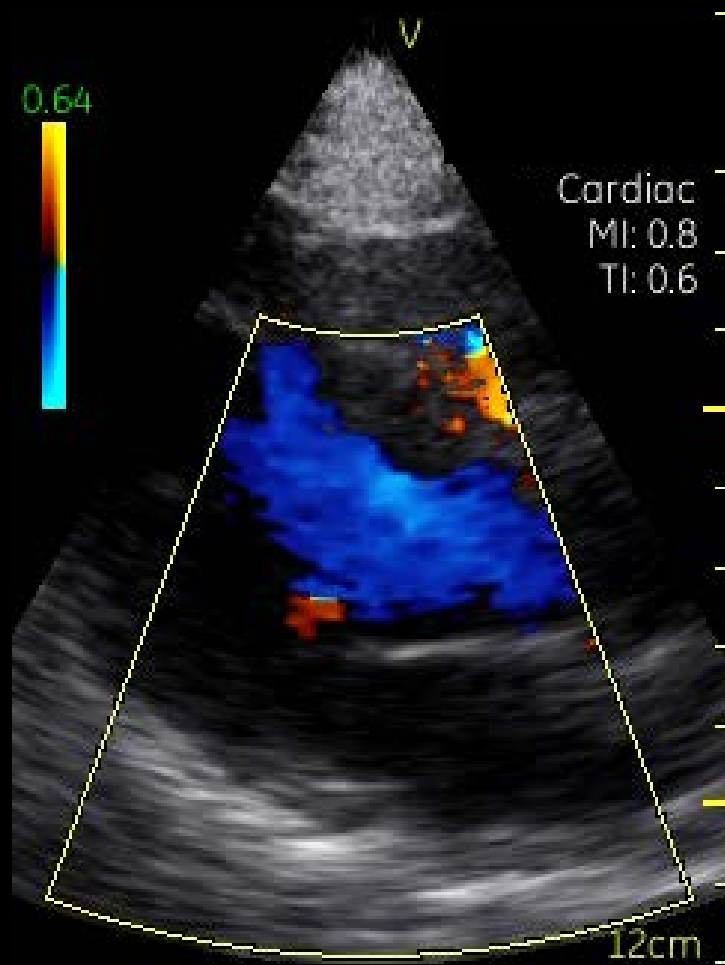


Apical 4 CH with TR

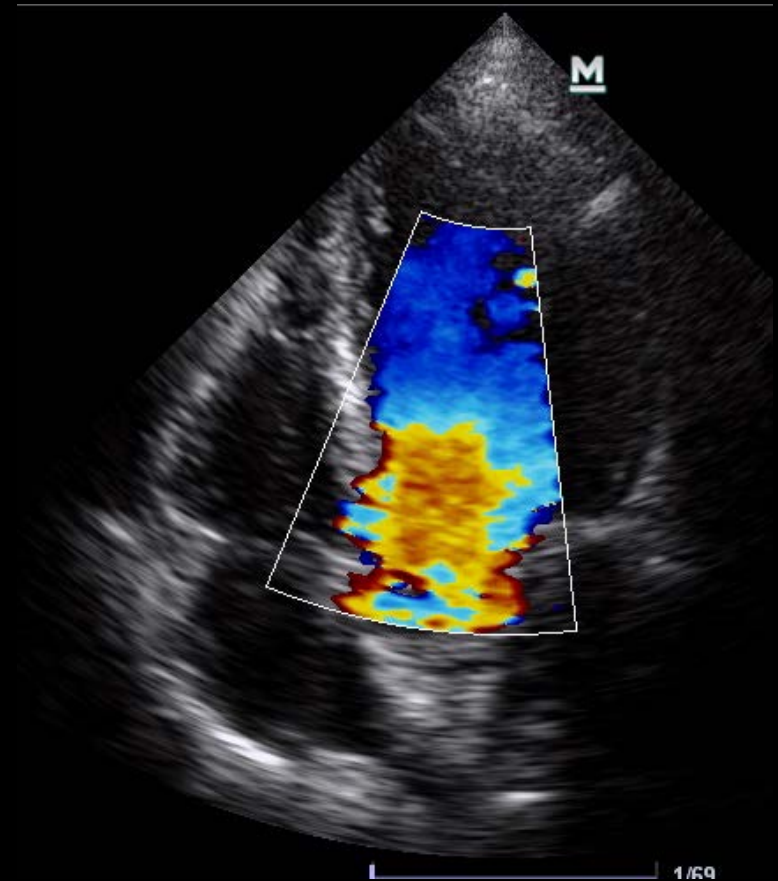
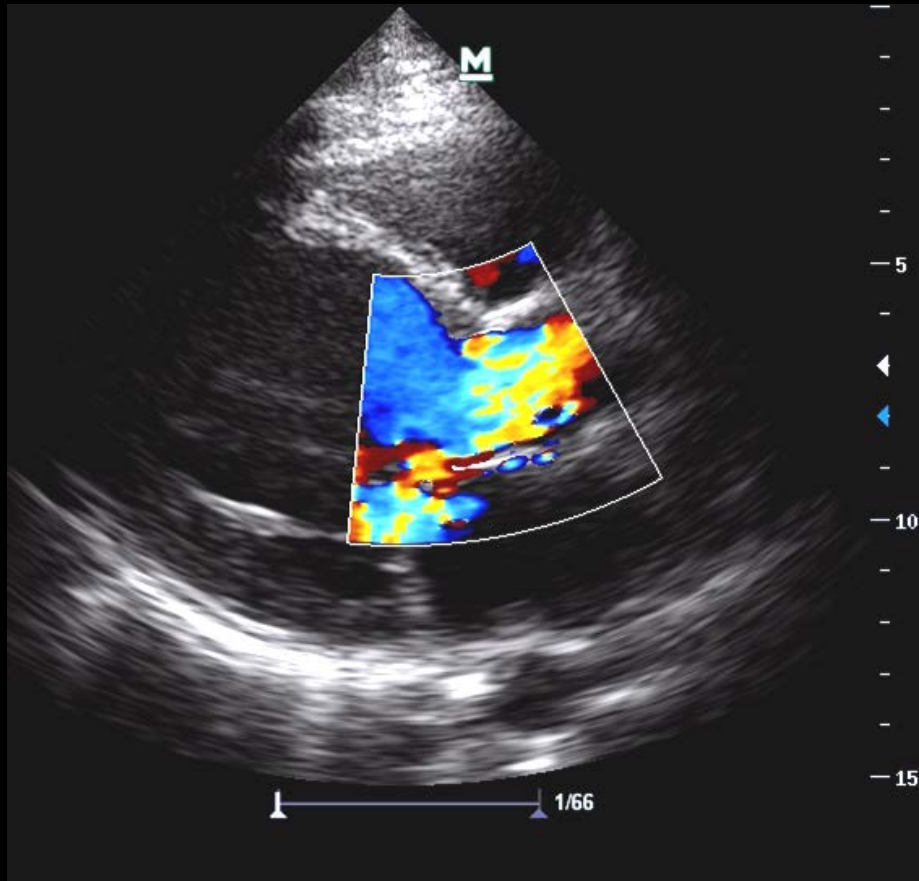


Normal

Mod - AR



AI



Quincke's Pulse

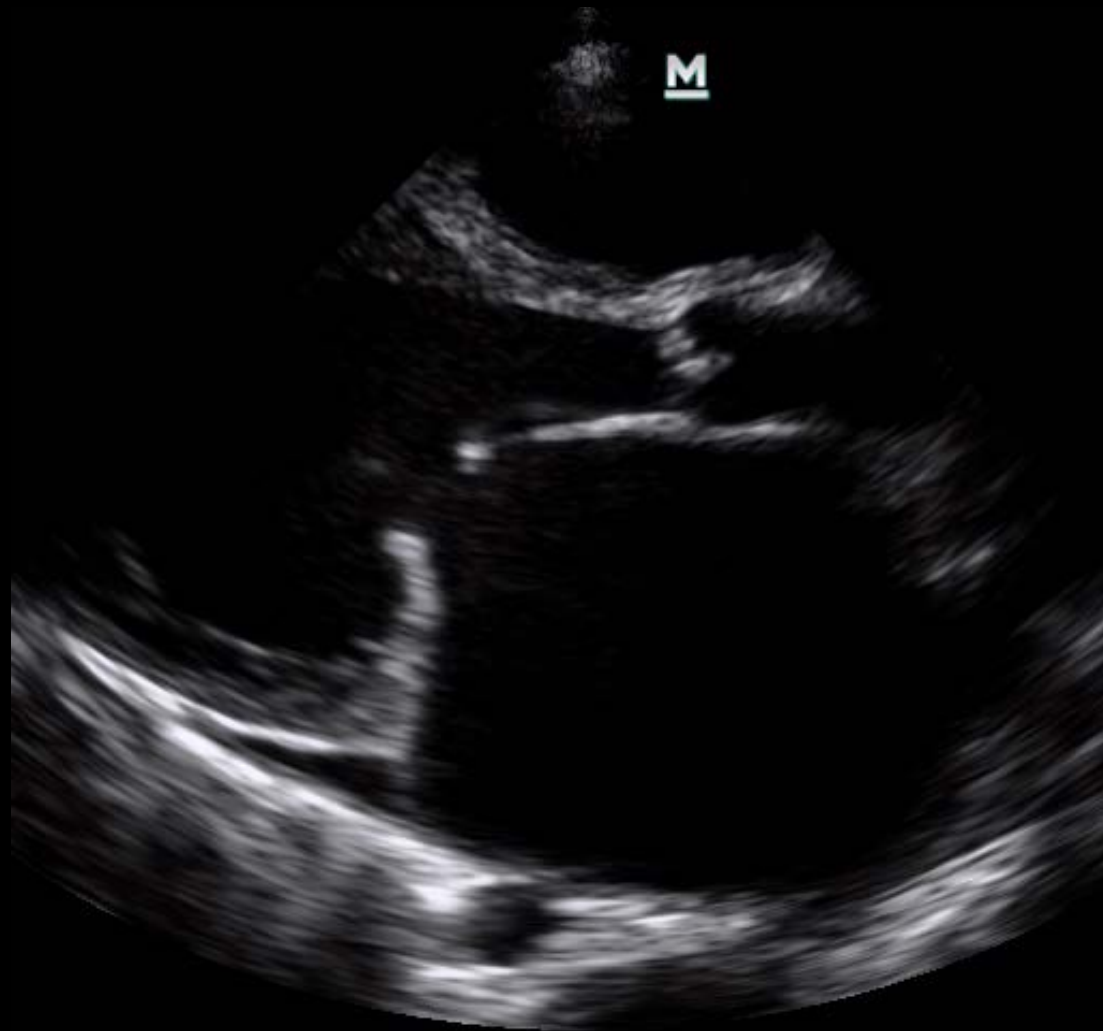

Heinrich Quincke

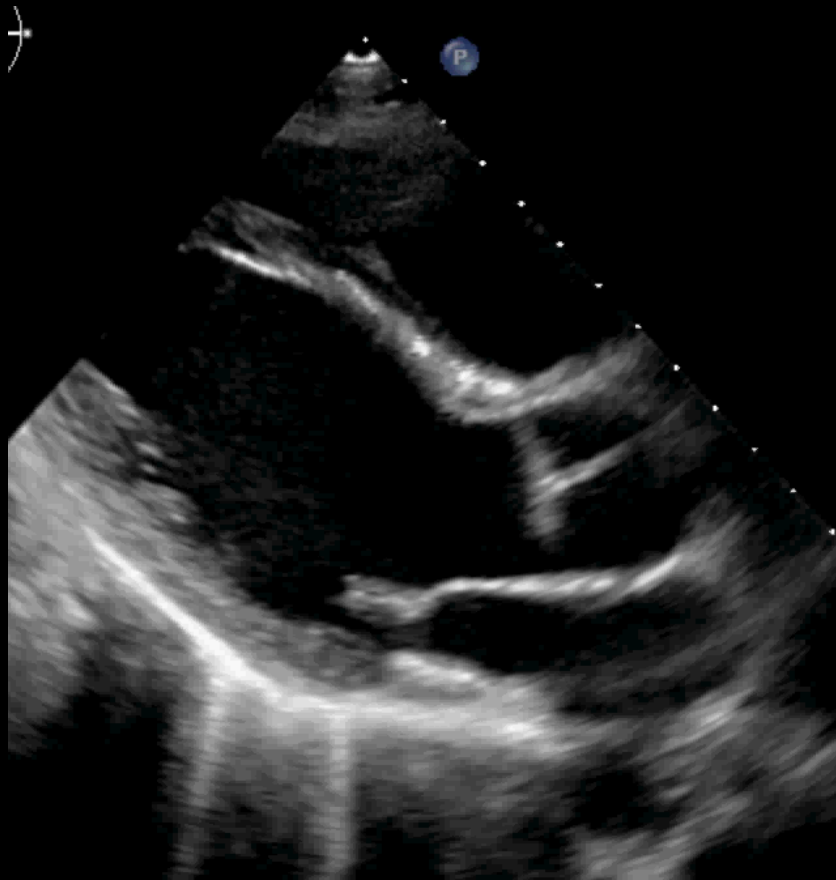
- German internist & surgeon (1842-1922)
- 1st to do lumbar punctures
- Described angioedema (Quincke's edema)
- Equated redness / blanching, pulsating nail beds to AI



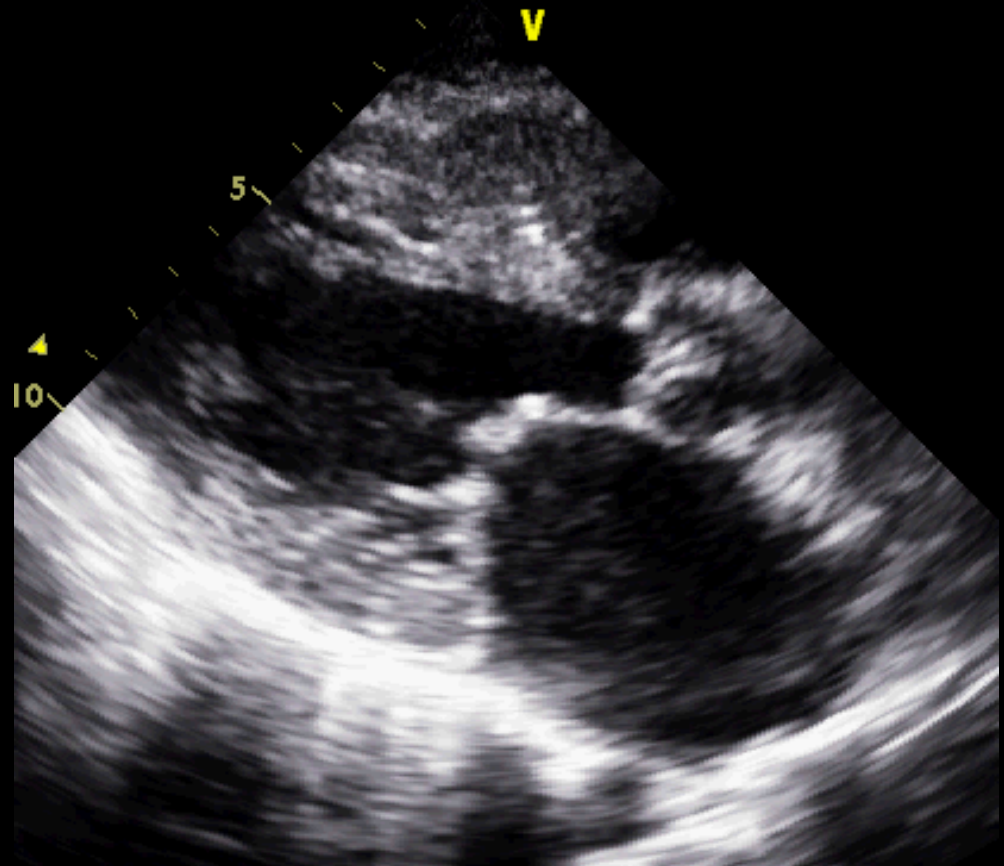
PLAX - Rheumatic MV Dz



Normal



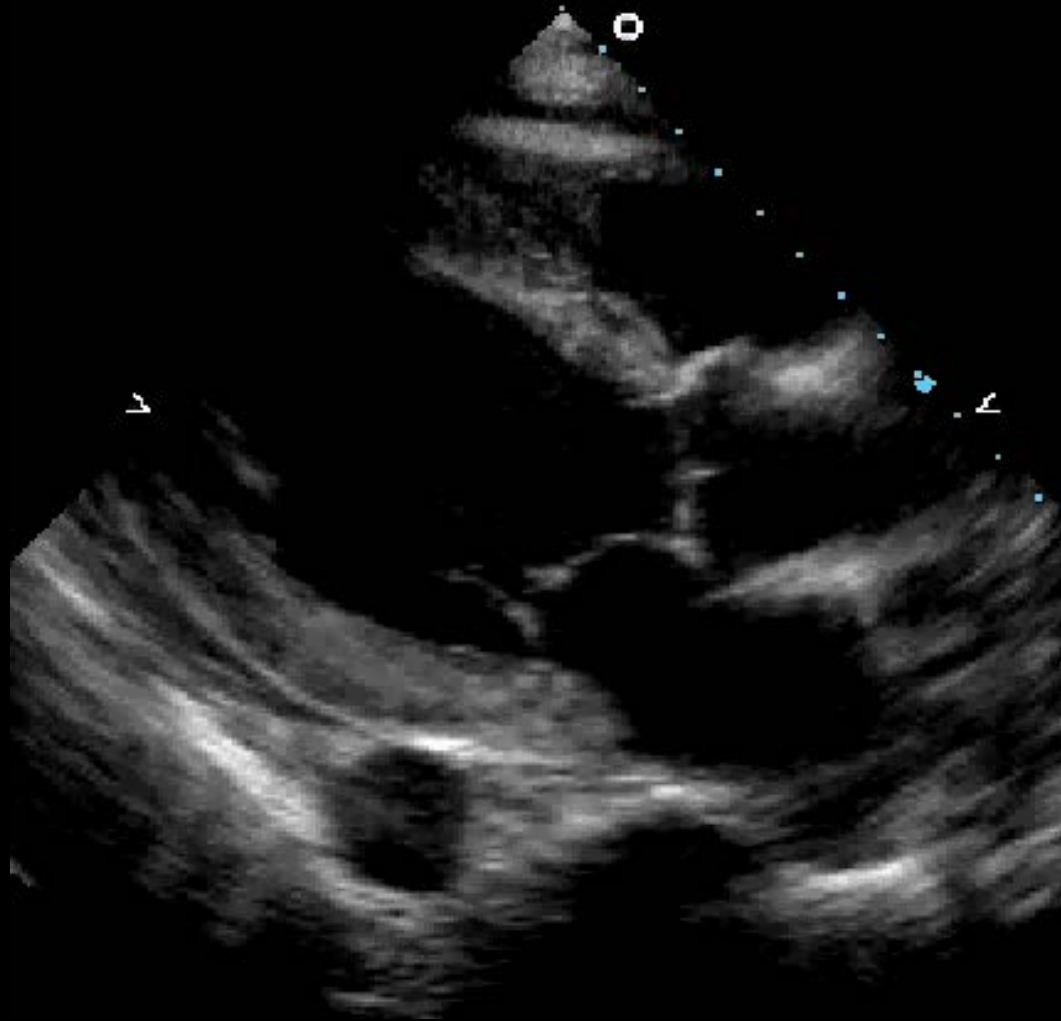
AS & MS



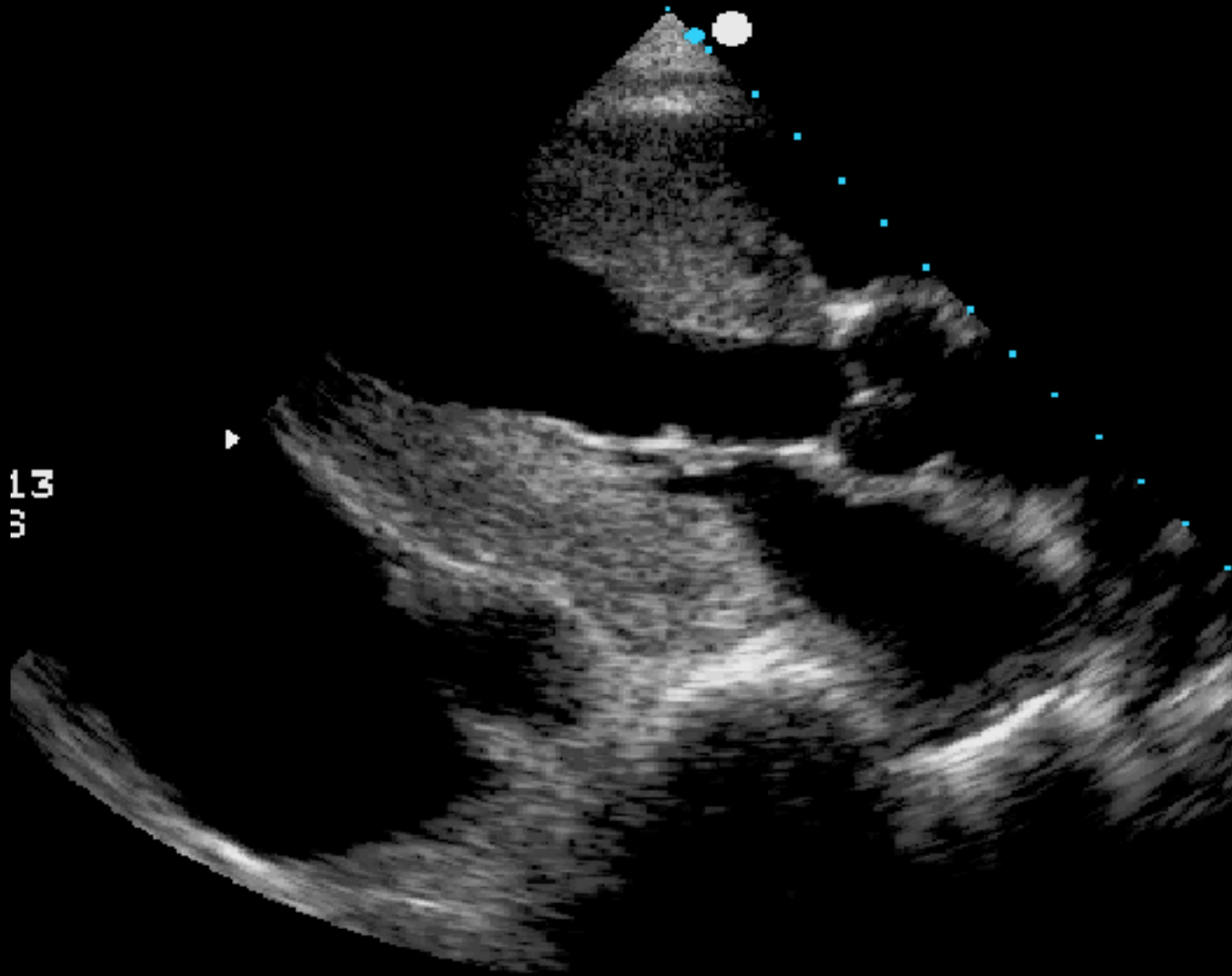
Cases

- PE, Tamponade
- Dilated chambers
- MR, TR, AI
- Hypertrophies

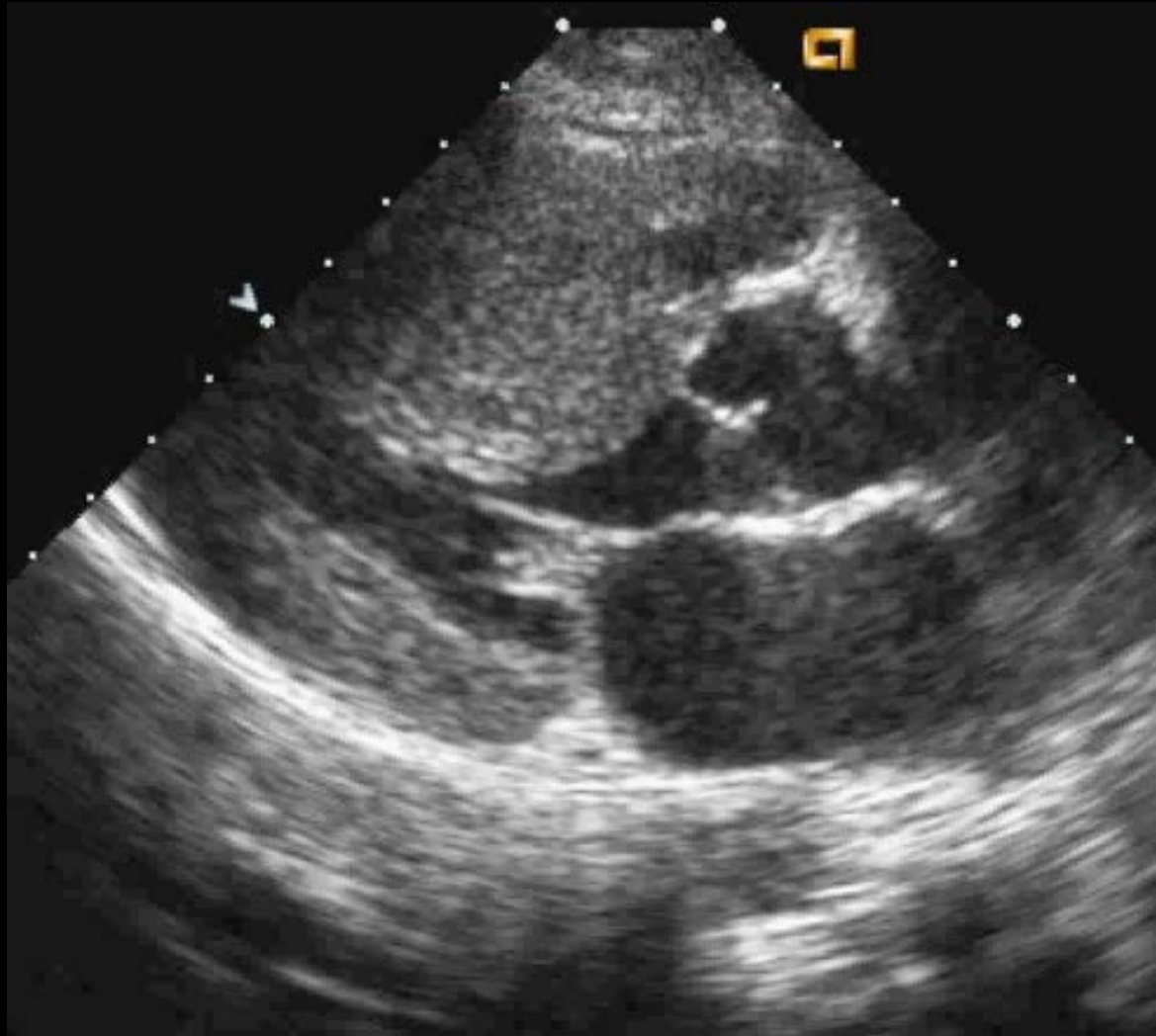
Hypertensive LV



Infiltrative CM



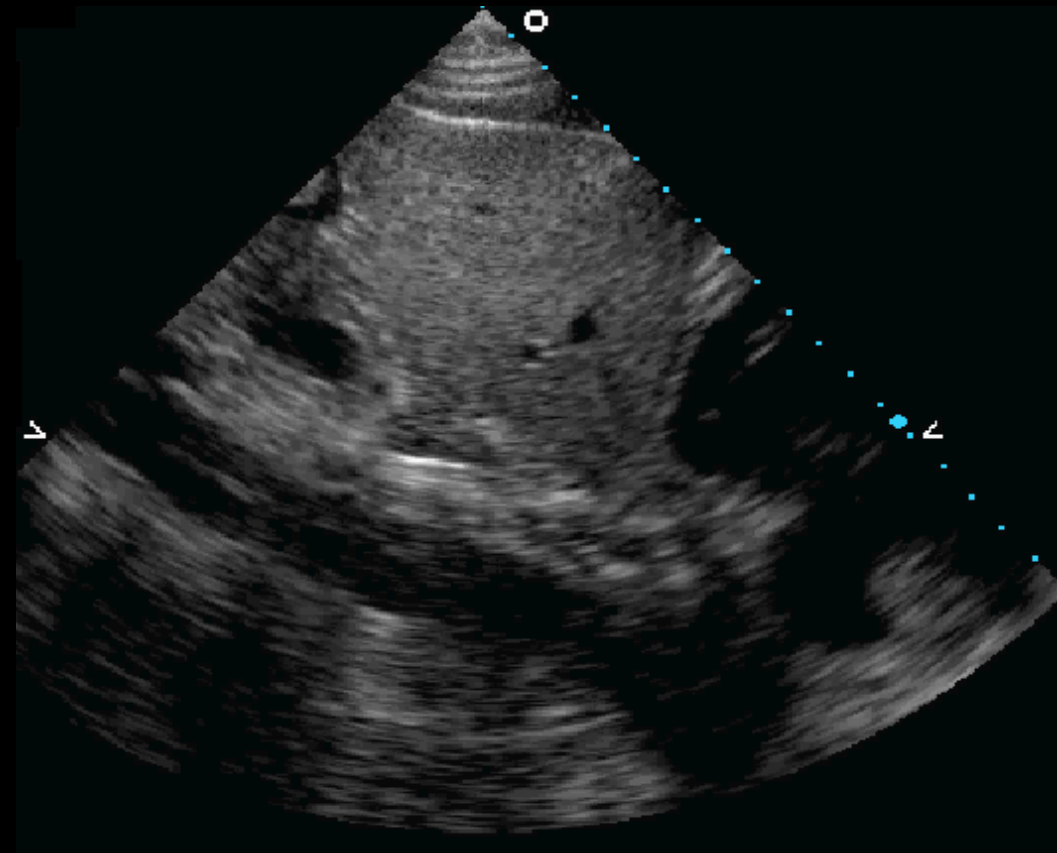
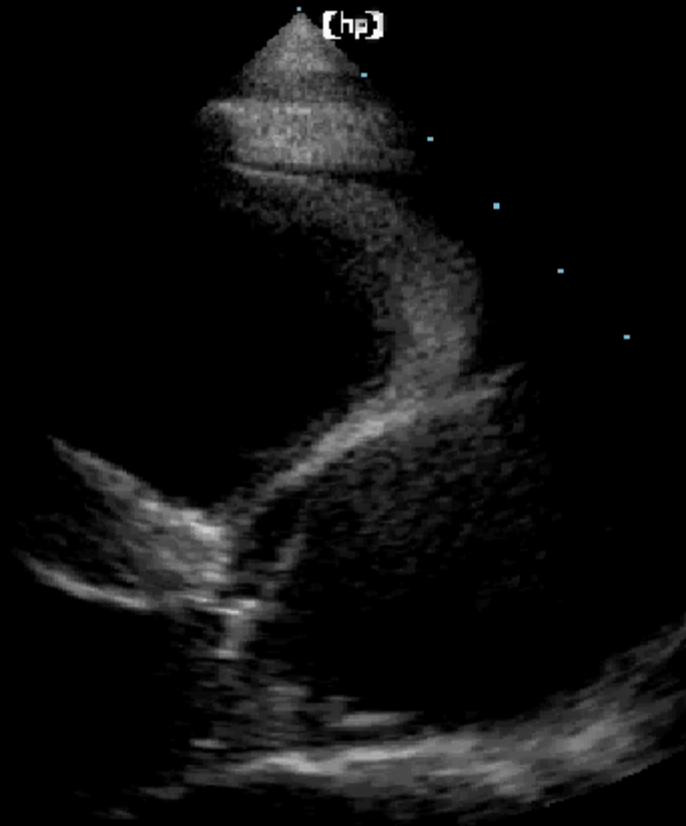
Hypertrophic CM



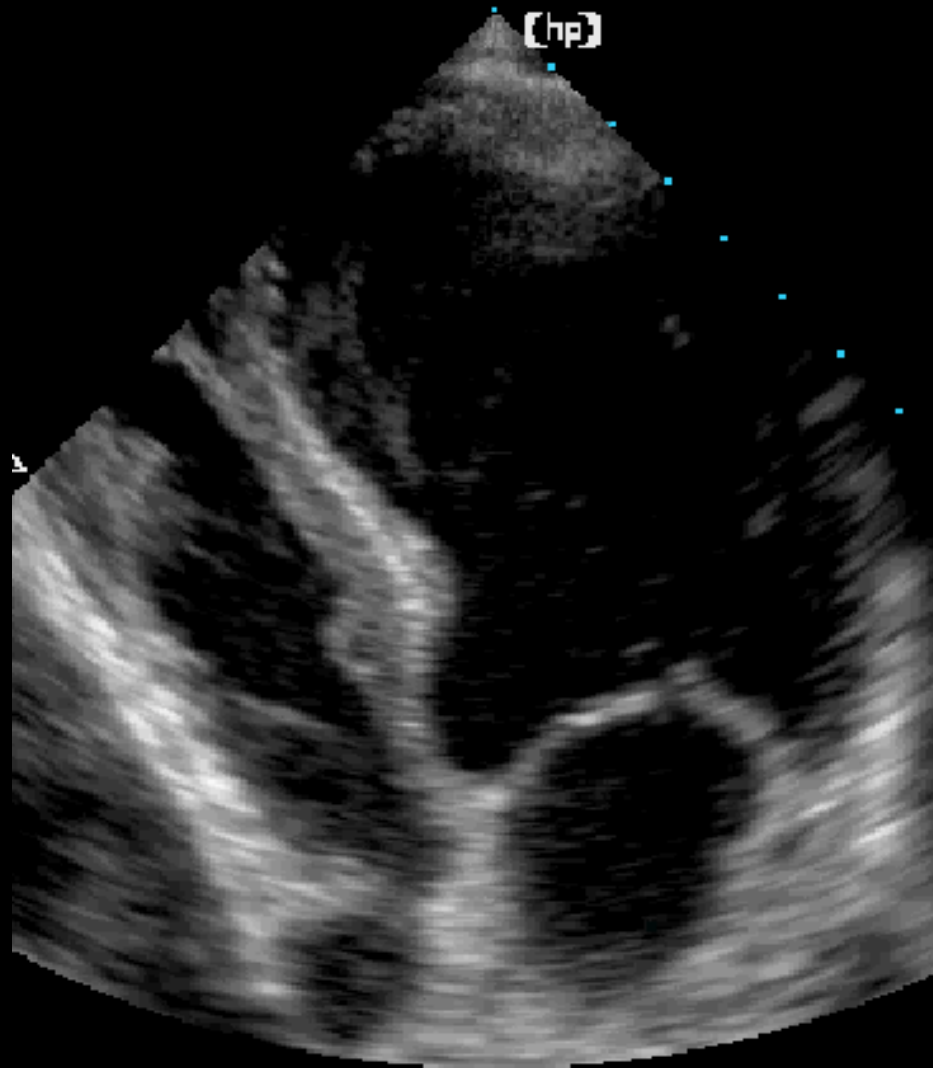
Cases

- PE, Tamponade
- Dilated chambers
- MR, TR, AI
- Hypertrophies
- Assorted stuff

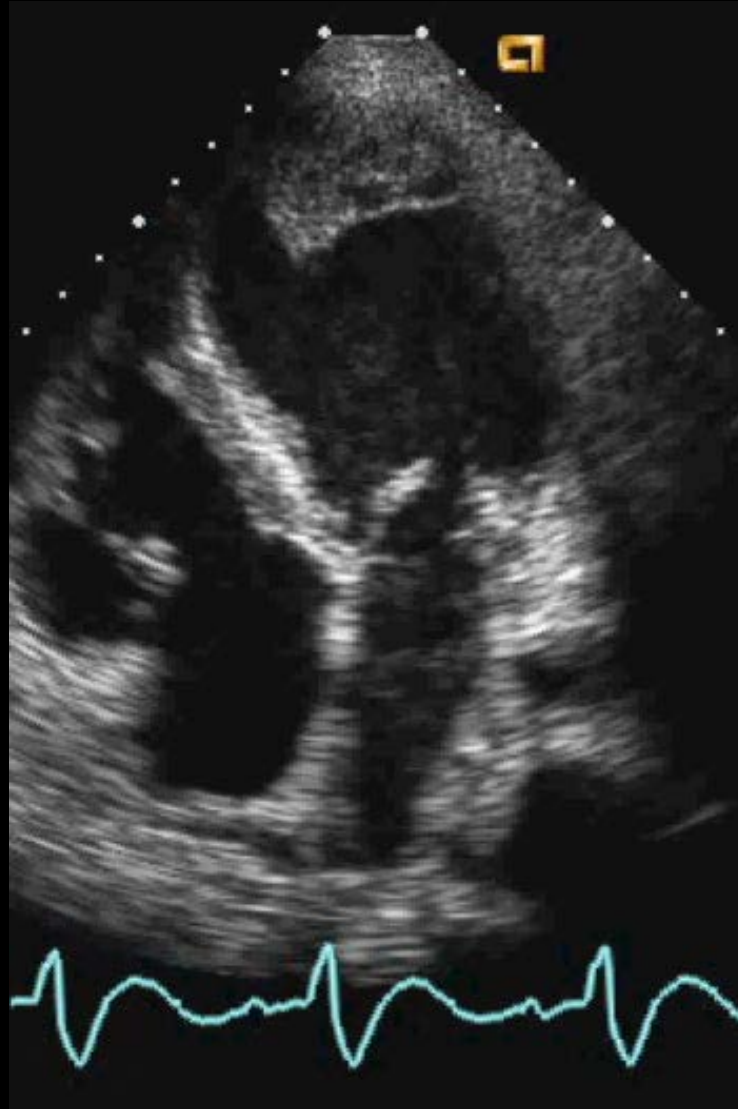Aortic Dissection



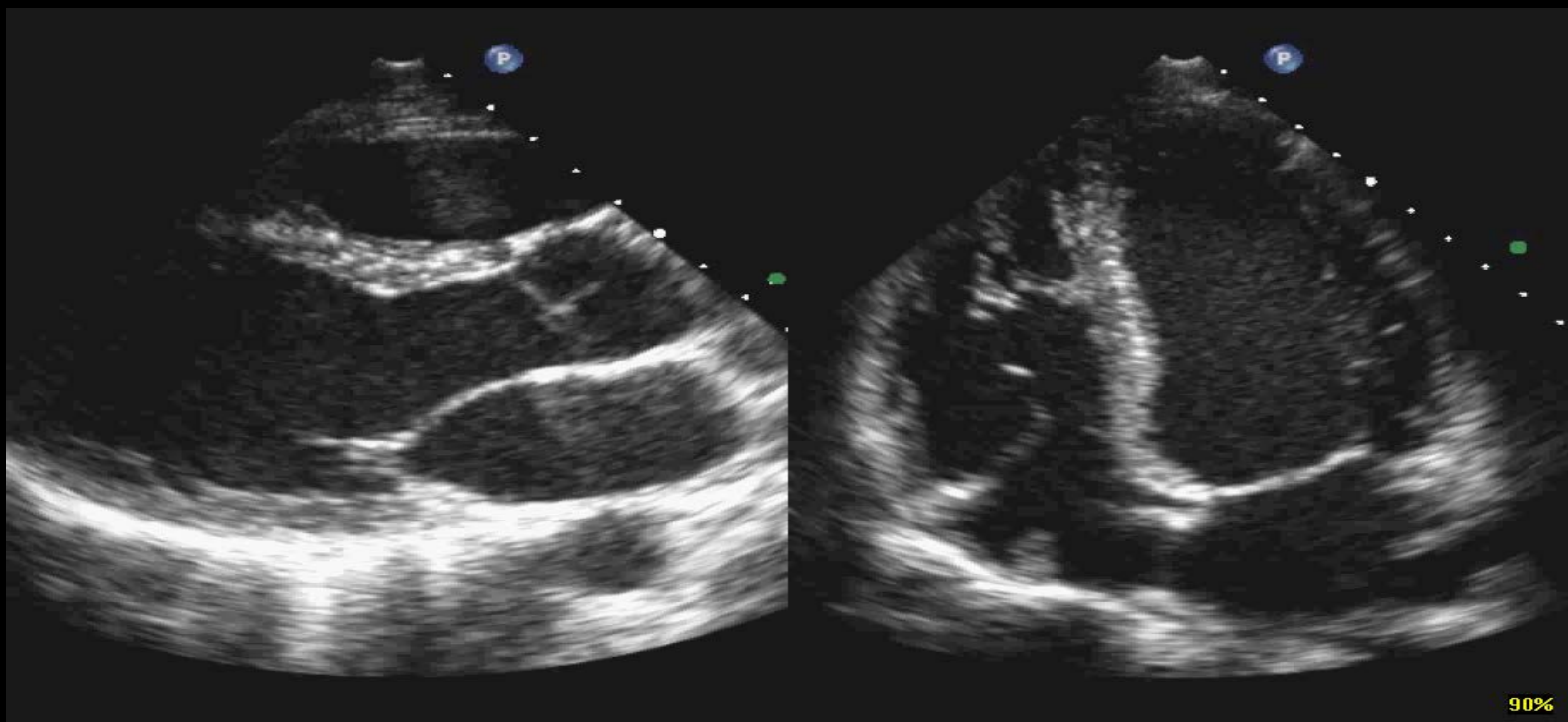
LV Aneurysm



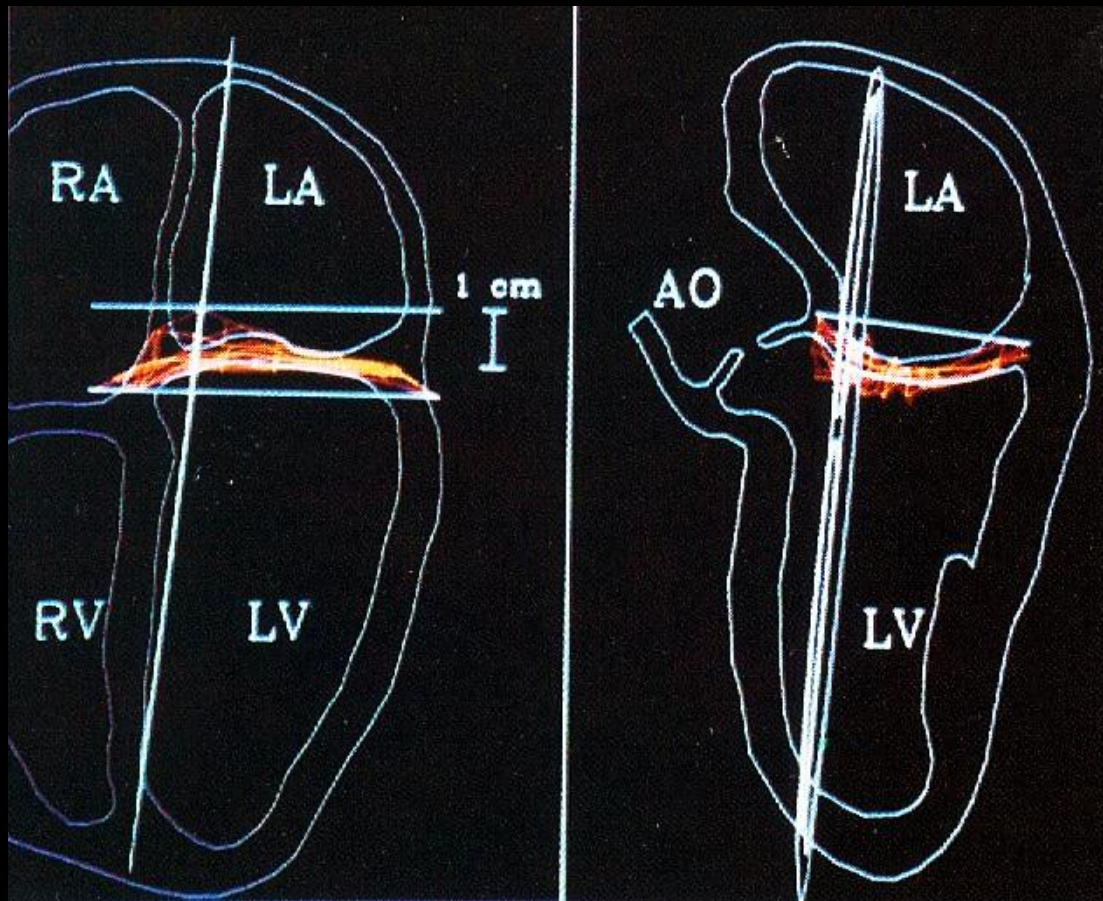
Apical Thrombus



No MVP from Apical 4-Ch



1989 MV Anatomy



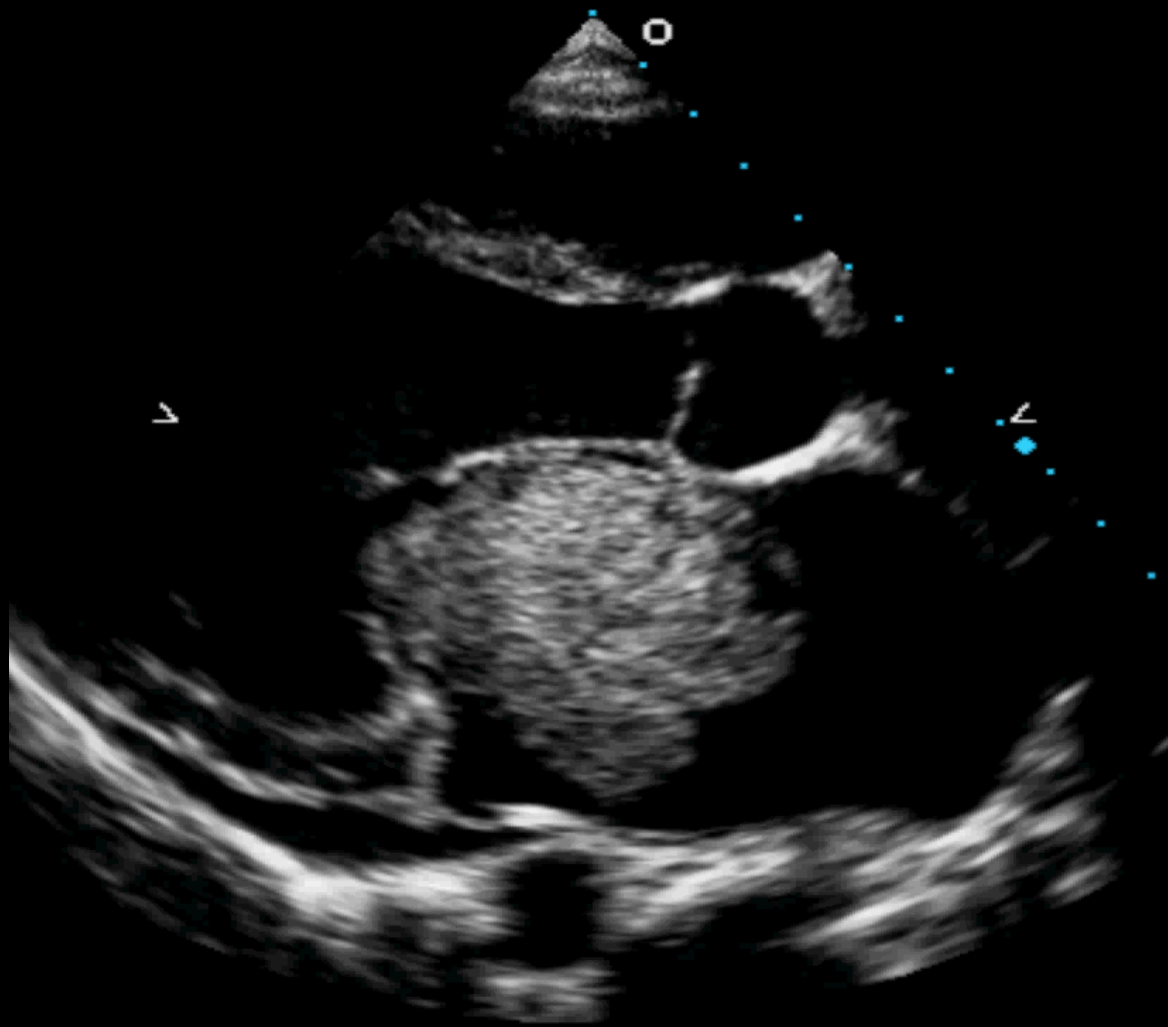Dr. Bob Levine,
et al at MGH

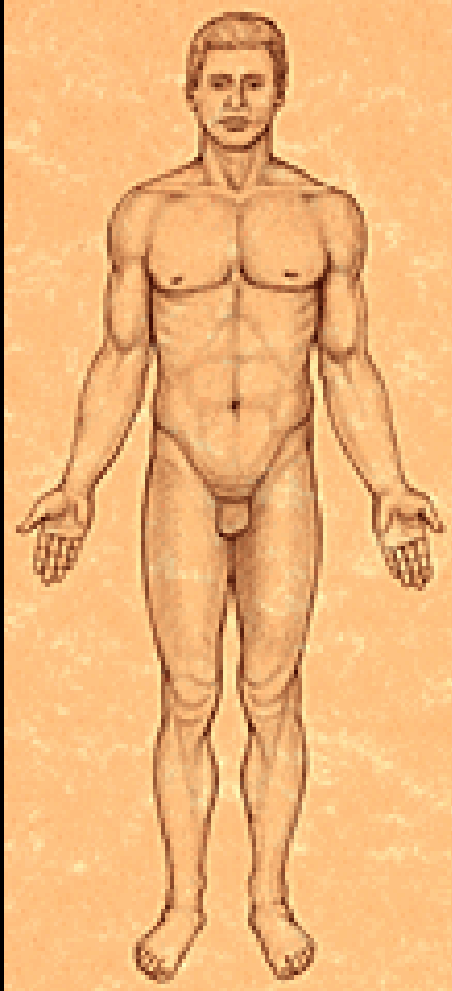
4 Chamber

Long Axis

Last One

LA Myxoma





The End